

CORRELATION OF PARATHYROID HORMONE-1 RECEPTOR EXPRESSION TO BONE METASTASIS OF BREAST CARCINOMA PATIENTS

Tusta-Adiputra, P. A., and Wibawa-Manuaba, I. B. T.

Surgical Oncology Subdivision, Department of Surgery, Faculty of Medicine, Udayana University/Sanglah General Hospital, Bali-Indonesia

Background: Bone metastasis is a common complication of metastasis of breast cancer and it is a unique pathobiology process. The Parathyroid Hormone-related Peptide (PTHrP) is a protein which has an important role in breast cancer cells to invade and infiltrate bones or bone marrow and accelerate angiogenetic process. The objective of this study is to reveal the relationship of PTHrP receptor named Parathyroid Hormone-1 Receptor (PTH1R) expression to bone metastasis in breast cancer patients. **Methods:** This was an analytical cross-sectional study, applying a non probability consecutive sampling. Samples were divided into two groups, i.e. one group of breast cancer metastasis to bone (+others) and another group with non-bone metastasis. Patients were collected from an existed data base (from medical record, cancer register, histopathology), since 2007. The specimen paraffin blocks were re-examined using IHC technique for PTHrP receptor. The data were analyzed and tested with Chi-Square (X^2), otherwise it would be tested using Fisher Exact Test. Each group would be allocated minimal of 17 patients/samples. **Results:** The Chi-Square test failed to show the association between PTH1R expression in breast cancer patients with bone metastasis ($p=0.295$). The relative prevalence result for positive PTH1R expression was 1.48. There was no proof that positive PTH1R expression was an associated factor for bone metastasis (95% confidence interval). **Conclusion:** PTH1R expression is not a factor associated with bone metastasis in breast cancer patients.

Keywords: PTH1R expression, bone, metastasis, breast carcinoma.

INTRODUCTION

Metastatic breast cancer is an incurable disease. The main goal of therapy for this disease is to reduce the symptoms, to prevent the complication from the progressing disease, and to improve quality of life for as long as possible. Bone metastasis is an important problem in breast cancer because it causes hypercalcemia and other skeletal-related events (SRE) such as pathological fracture, spinal cord compression and pain. Bone is the most common site for metastasis of breast cancer, and is the most common site (47-85%) for metastasis of any cancer. Patients with bone metastasis of breast cancer can significantly survive longer than patients with non-bone metastasis of breast cancer, with mean life expectancy around 24-30 months. Approximately 70% of patients who die from breast cancer had bone metastasis prior to death, and in 40% of those, bone is the first place where the metastasis occurred. This places them at high risk for morbidity such as pathological fracture of the vertebrae, long bones, pelvic, ribs and other multiple fractures. Aside from that, spinal cord

compression and nerve root compression can also occur as a result of vertebrae instability and pathological fracture.¹⁻³

It is believed that Parathyroid Hormone-related Peptide (PTHrP) plays an important role in development of bone metastasis. PTHrP is a protein consisting of 139-173 amino acids, normally produced by tissues such as brain, pancreas, breast, heart, lung and placenta. PTHrP plays a role in growth and development of breast glands, the development of teeth and bone, and also central nervous system. PTHrP has no role in the regulation of calcium balance, except in malignancy.^{4,5}

PTHrP has one receptor named Parathyroid Hormone-1 Receptor (PTH1R) located in the kidneys and bone. The effect of PTHrP in bones are catabolic effects through osteoblastic stromal cell which, when secreted in normal amount, has a role in bone formation. If it is excessively expressed, such as in malignancy, this peptide will cause bone resorption (osteoclastic bone resorption) that is mediated by osteoclasts and may cause hypercalcemia as well as increasing the risk of pathological fracture. The effect of PTHrP in the kidneys is the stimulation of cyclic-Adenosine Monophosphate (c-AMP) which may increase the reabsorption of calcium and the excretion of phosphate in turn, will cause hypercalcemia, hypophosphatemia, and hyperphosphaturia.⁴⁻⁸

The role of PTHrP in determining the development of bone metastasis especially in breast

Address for correspondence:

Putu Anda Tusta Adiputra

Surgical Oncology Subdivision, Department of Surgery, Faculty of Medicine, Udayana University/Sanglah General Hospital, Bali-Indonesia

E-mail: andatusta@yahoo.co.id

malignancy occurs through a few mechanisms, such as: increasing the ability of cancer cells to invade and infiltrate bone marrow, triggering the angiogenesis process, and supporting tumor proliferation by producing cytokines and transforming growth factor- β (tumor growth factor- β) that will provide a good environment for tumor cell growth in the bone. PTHrP has clinical importance in breast cancer, both in early breast cancer (EBC) and in bone metastasis breast cancer (BM). This has been proven in a study conducted in England, which concludes that the expression of PTHrP is seen in 115 of 170 EBC (68%) and 100% in BM, while the receptor is also seen in 37% EBC and 81% BM, that, in its turn, is also associated with the increasing morbidity as a result of bone metastasis and also with the decrease in life expectancy.⁹

MATERIAL AND METHODS

The expression of PTHrP is measured by examining the receptor (PTH1R) in the tissue of breast cancer primary tumor with bone metastasis using immunohistochemistry examination. This study design is cross-sectional analytical study. This study was conducted in Oncology Subdivision and Anatomical Pathology Department of FK Unud/ RS Sanglah, Denpasar, starting on November 2009, using the data from 2007 until the subject quota was reached. The subjects of this study are patients with stadium IV breast cancer treated in the Oncology Subdivision of FK Unud/RS Sanglah, Denpasar from 2007 with a complete medical record and a paraffin block sample available for examination in Anatomical Pathology Department of Faculty of Medicine Udayana University/Sanglah General Hospital, Bali-Indonesia. The subjects are selected based on non-probability sampling using consecutive sampling technique. The subjects are divided into two groups, the intervention group (patients with bone metastasis breast cancer) and control group (patients with non-bone metastatic breast cancer) that acts as an internal control group.

A patient is excluded from participating if they had or are having a primary pathology in their bones (such as fractures, bone primary tumor, osteoporosis and implants). Other exclusion criteria are patients whose expression cannot be detected on IHC stains and patients with primary hyperparathyroidism. The primary antibody of PTH1R is Mouse Monoclonal Antibody solution, coded CAT#MS-1270-P0 is able to detect PTH1R. For this study, 1:100 dilution was applied. The sample is examined under a microscope using 400 times magnification. Positive result is defined as more than 10% cut-off points. All results are calculated in 10 times transfer reading, and then calculated for average point. For positive control, we use breast carcinoma. The expression of PTH1R can be seen in the brownish-stained cytoplasm.

Chi-square test and Relative Prevalence Analysis is conducted using SPSS 15 Windows program for normal distribution. If the requirement for normal distribution is not fulfilled, we use

Fisher-Exact test. Data precision is determined with 95% CI, and acceptable statistical significance is $p < 0.05$.

RESULTS

The data for this study was collected for three years, starting from 2007 to 2009. During that period, we accumulated 50 study subjects who meet the inclusion and exclusion criteria. From the 50 subjects found, 18 were subjects with bone metastasis and 32 with non-bone metastasis. From the PTH1R expression examination we got 22 subjects with positive results and 26 with negative results, and two subjects were excluded from the analysis because no tumors were found in the microscopic examination.

From 48 study subjects, 27 (56.25%) originated from Bali, and 21 (43.75%) were from outside of Bali (Java, Lombok, Sumbawa and Flores). The educational level of our subjects are high school graduates (26 subjects, 54.17%), junior high school graduates (15 subjects, 31.25%) and subjects with bachelor degree (7 subjects, 14.58%). All of the subjects in this study are women, with mean age of 48 years (SD 10.824), with the youngest being 29 years old and the oldest being 78 years old. The TNM degree of the subjects ranges between T3N2M1 to T4dN2M1. From 48 patients with breast cancer, 25 (52.1%) have their cancer on the right side, while 23 (47.9%) have their cancer on the left side of their breast. Based on menopausal status, 24 (50%) were premenopausal, and the other 24 (50%) were postmenopausal (Table 1).

Table 1

Distribution of Patients with Breast Cancer based on age groups, TNM staging and type of metastasis

Variables	Number	Percentage (%)
Age group		
20 – 29	1	2.1
30 – 39	11	22.9
40 – 49	18	37.5
50 – 59	10	20.8
60 – 69	7	14.6
> 70	1	2.1
TNM staging		
T3N2M1	1	2.1
T4bN1M1	11	22.9
T4bN2M1	13	27.1
T4bN3M1	2	4.2
T4cN1M1	3	6.3
T4cN2M1	14	29.2
T4cN3M1	3	6.3
T4dN2M1	1	2.1
Type of Metastasis		
Bone	18	37.5
Non Bone	30	62.5
Total	48	100

Table 2 is a table showing the variables of mean age, menstrual status, histopathological grading and the distribution of metastasis (bone and non-bone). From all 48 subjects, regardless of the type of metastasis, we found 22 (45.8%) positive expressions of PTH1R and 26 (54.2%) negative expressions of PTH1R.

Table 2
Distribution of Age, Menstrual Status, and Histopathological Grading on Types of Metastasis

Variables		Bone	Proportion (%)	Non Bone	Proportion (%)	Total
Average age (years)		47.61±11.8		48.73±10.4		
Menstrual Status	Premenopausal	10	55.6	14	46.7	24
	Post-menopausal	8	44.4	16	53.3	24
Grade	I	9	50	6	20	15
	II	5	27.8	17	56.7	22
	III	4	22.2	7	23.3	11

Table 3 shows positive PTH1R expression is seen in 10 patients with bone metastasis out of 22 subjects with positive expressions (45.5%), and in 12 patients out of the 26 subjects with non-bone metastasis of breast cancer.

Table 3

Crosstab of Distribution of Patients with Breast Cancer based on Types of Metastasis with PTH1R Expression

PTH1R	Metastasis			
	Bone (n)	Proportion (%)	Non Bone (n)	Proportion (%)
Positive	10	45.5	12	54.5
Negative	8	30.8	18	69.2

The proportion of subjects with bone metastasis expressing PTH1R is 10 out of 18 (55.6%) subjects, while the proportion of subjects with bone metastasis that did not express PTH1R is 8 out of 18 (44.6%) subjects. On the contrary, on subjects with non-bone metastasis, we found 12 (40%) patients out of 30 who shows PTH1R expression and 18 (60%) out of 30 who did not show PTH1R expression.

Positive expression of PTH1R is shown in the cytoplasm with a brownish color (Figure 1).

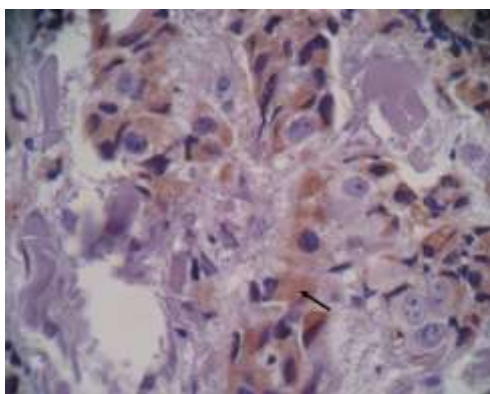


Figure 1

The positive expression of PTH1R is shown in the cytoplasm with a brownish color

Statistical analysis using Chi-square shows no significant relationship between the expression of PTH1R with bone metastasis on breast cancer

patients, with $p = 0.295$. Even though the relative prevalence of positive PTH1R expression on the development of bone metastasis in this study is 1.48 (95% CI: 0.708 – 3.084), 95% confidence interval alone cannot conclude that positive PTH1R expression is a factor associated with bone metastasis.

DISCUSSION

Mundy and Guise concluded that bone is one of the most common for any metastatic malignancy after lung and the liver. Approximately 30% of all malignancies will develop bone metastasis, and in breast cancer, 25% of patients with EBC will progress into bone metastasis breast cancer; the number is even as high as 75-80% for patients with advanced breast cancer.⁷ A few studies showed that in women with breast cancer, in a five-year follow up, 30% of the patients will progress into bone metastasis, and more than half of that population will progress or exacerbate in the first two years after the diseases was diagnosed and the staging established. More than 70% of women who died of breast cancer did not develop bone metastasis, whether the diagnosis is pre-mortem or postmortem, and 20% of them will have bone metastasis after 5 years post-surgery. Twenty-five percent of patients with EBC will progress into bone metastasis and 75% patients with LABC will progress into bone metastasis.^{9,10}

In this study, we found that from 48 subjects of patients with breast cancer, 18 (37.5%) had bone metastasis and 30 (62.5%) had non-bone metastasis. Another studies showed approximately similar results. A study by Cole (1991) showed that from 49 patients with breast cancer studied and followed up for 30 months, 12 (24.5%) developed bone metastasis. Another study by Mansi (1991) showed that from 350 subjects who were studied and followed up for 76 months, 107 (30.6%) developed bone metastasis.¹¹

The impact of bone destruction can be seen with plain radiography examination. Usually, an osteolytic or osteosclerotic lesion is found, which characterizes certain bone metastasis. A lytic lesion is usually found in breast cancer, lung cancer, kidney cancer and myeloma. These lesions show thinning trabecula and shows no clear boundaries between the lesion and normal bone tissues. Prostatic cancers generally develop sclerotic lesions, but these lesions can also be found in breast cancer and in a carcinoid tumor. These lesions appeared nodular, round with sclerotic

areas. Plain radiography visualizes bone structures and 30-75% of normal bone mineral contents must be depleted before these lesions can become clear in plain radiography examination. It takes a few months before they can be detected using this modality. Plain radiography, in this case a bone survey, is around 44-50% less sensitive compared to bone scintigraphy. The radiation exposure of abdominal CT is equal to that of 500 plain chest X-rays. A stricter patient selection is recommended for the use of CT. However, a CT can provide a more detailed picture of bone metastasis. A CT examination can provide both osteolytic and osteoblastic lesions with their extensions in great detail. A CT examination can visualize bone structure, presence of tumor in bone marrow, and also can detect an early metastasis in bone marrow. The sensitivity of CT is reported to range between 71% and 100%. The disadvantage of CT examination lies in the lack of ability to provide a picture of spine metastasis because of the limitation in the movement of a CT table. For a suspected spine lesion, another imaging modality is recommended. Bone scintigraphy examination has 62-100% sensitivity and 72-100% specificity. The radioisotope used in this examination is radionucleotide (^{99m}Tc -metilen diphosphonate/ ^{99m}Tc -MDP) and the radioactivity distribution is recorded with a gamma camera. This radionucleotide is absorbed by calcium hydroxyapatite in the bone, a process that is affected by the increase of local blood flow. Osteoblastic activity has 95% sensitivity in detecting bone metastasis, but the specificity is low. Degenerative diseases, infections and fractures can yield a false positive result. Further imaging is needed for diagnosis.¹²

Parathyroid hormone-related peptide was first identified in 1980s as a product of tumor with an ability to activate the PTH receptor and causes hypercalcemia. PTHrP possesses a genetic structure that is similar to parathyroid hormone and is a protein with 139-173 amino acids. This peptide is normally produced by several tissues such as brain, pancreas, heart, lung, breast and placenta.^{4,5} Both PTHrP and PTH have one receptor that is called PTH-1 (PTH1R) that is located in kidneys and bones. PTHrP has catabolic effect to bones through osteoblastic stromal cell, which when secreted in normal amount, plays a role in bone formation. If it is excessively expressed, such as in malignancy, this peptide will cause bone resorption (osteoclastic bone resorption) that is mediated by osteoclasts and may cause hypercalcemia as well as increasing the risk of pathological fracture.⁵

Linforth, in a study aimed to determine the expression of PTHrP and PTH receptor in EBC and bone MBC, showed that PTHrP was expressed in 68% of patients with EBC and 100% of patients with bone MBC. The mRNA (PTHrP receptor) was expressed in 50% of patients with EBC and 80% of patients with bone MBC. Both PTHrP and mRNA are expressed in 37% of patients with EBC and 81 patients with bone MBC.⁹

Individually, PTHrP and PTHrP receptor are also associated with the decrease in Disease-free Survival and PTHrP receptor itself is associated

with the decrease in Overall Survival. A positive expression of PTHrP without an expression of PTHrP receptor is better compared to a negative PTHrP expression with a positive expression of PTHrP receptor.

In Table 3, the result of our study shows a basic correlation between subjects with bone and non-bone metastasis with the occurrence of a negative or positive expression of PTH1R. The data obtained shows that the proportion of subjects with bone metastasis expressing PTH1R is 10 out of 18 subjects (55.6%) whereas the proportion of subjects with bone metastasis with no PTH1R expression is 8 out of 18 subjects (44.6%). A contrary result is found in the subjects with non bone metastasis, with the proportion of 12 out of 30 subjects (40%) expressing PTH1R and 18 out of 30 subjects (60%) with no PTH1R expression. The expression of PTHrP shows an approximately similar result, when associated with the development of bone metastasis. A positive PTH1P expression is shown in 22 subjects (45.8%) and negative PTH1R expression shown in 26 subjects (54.2%).

A statistical analysis using Chi-Square showed no correlation between PTH1R expression with bone metastasis in patients with breast cancer, with $p=0.295$. Even though the relative prevalence of positive PTH1R expression to the development of bone metastasis in this study is 1.48 (95%CI : 0.708 – 3.084), 95% confidence interval alone cannot conclude that positive PTH1R expression is a factor associated with bone metastasis.

Even though the result of this study shows that the number of patients with non-bone metastasis with positive PTH1R expression is greater than that of the patients with bone metastasis, the patients with bone metastasis shows more tendencies towards a positive expression of PTH1R receptor. This result is in accordance to that of a study conducted by Powell, which showed that the detection of PTHrP using IHC in primary breast cancer and metastatic tumors can be used more as a predictor of development of bone metastasis than as a predictor of non-bone metastasis. Sixty percent of patients with primary breast cancer detected using IHC expressed PTHrP. But when detected in metastatic tumor, 92% of patients with bone metastasis of breast cancer expressed PTHrP/PTHrP receptor, and only 17% of patients with non-bone metastasis of breast cancer expressed PTHrP.

The limitation of this study is in the limitation of diagnostic device, which yields the diagnosis in the subjects used in this study to be somewhat less ideal. To assess bone metastasis in this study, we can only use bone survey without any bone scan, and thus we cannot rule out the possibility that the subjects with non-bone metastasis has also developed bone metastasis that is not detected by bone survey.

Another limitation of this study is that the measurement of PTH1R expression using IHC is a semi-quantitative measurement, which potentially makes the study result to be less powerful. A pure quantitative measurement will increase the power of this study.

CONCLUSION

The expression of PTH1R is not a factor associated with bone metastasis in patients with breast cancer, even though patients with positive PTH1R expression are 1.48 times more likely to develop bone metastasis compared to the patients with negative PTH1R expression.

ACKNOWLEDGMENT

The authors would like to thank the director of Sanglah General Hospital Bali-Indonesia for access to the hospital. Special thank was also dedicated to the head of Oncologic Surgery Department for access and aid during research.

REFERENCES

1. Hartsell WF. Bone Metastases in Specific Tumours: Breast Cancer. In: Jasmin C, Coleman RE, Coia LR, Capanna R, Saillant G. editors. Textbook of Bone Metastases. West Sussex: John Wiley & Sons Ltd; 2005.p. 470-82.
2. Coleman RE, Holen I. Bone Metastases. In: Abeloff MD, Armitage JO, Niederhuber JE, Kastan MB, McKenna WG. editors. Abeloff's Clinical Oncology. 4th Edition. Philadelphia: Churchill Livingstone; 2008.p. 845-71.
3. Theriault RL. Bone-Directed Therapy and Breast Cancer: Bisphosphonates, Monoclonal Antibody, and Radionuclides. In: Harris JR, Lippman ME, Monica M, Osborne CK. editors. Diseases of the Breast. 4th Edition. Philadelphia: Lippincott Williams & Wilkins; 2010.p. 1038-48.
4. Burtis WJ. Parathyroid Hormone-related Protein: Structure, Function and Measurement. *Clinical Chemistry*. 1992; 38 : 2171-83.
5. Strewler GJ. The Physiology of Parathyroid Hormone-related Protein. In: Epstein FH. Editor. Mechanisms of Disease. *N Engl J Med*. 2000; 342: 177-185.
6. Martin TJ, 1996. Actions of Parathyroid Hormone-related Peptide and Its Receptors. *N Engl J Med*, vol. 335, no. 10, September 5, 1996, pp. 736-738.
7. Mundy GR, Guise TA. Role of Parathyroid Hormone-related Peptide in Hypercalcaemia of Malignancy and Osteolytic Bone Disease. *Journal of Endocrinology*. 1998; 5: 15-26.
8. Dittmer A, Vetter M, Schunke D, et al, 2006. Parathyroid Hormone-related Protein Regulates Tumor-relevant Genes in Breast Cancer Cell. *The Journal of Biological chemistry*, vol. 281, no.21, May 26, 2006, pp. 14563-72.
9. Linforth R, Anderson N, Hoey R, et al, 2002. Coexpression of Parathyroid Hormone Related Protein and Its Receptor in Early Breast Cancer Predicts Poor Patient Survival. *Clinical Cancer Research*, vol. 8, October 2002, pp. 3172-77.
10. Iddon J, Byrne G, Bundred NJ, 1999. Bone Metastasis in Breast Cancer: The Role of Parathyroid Hormone Related Protein. *Surgical Oncology*, vol. 8, pp. 13-25.
11. Mansi JL, Easton D, Berger U, et al. Bone Marrow Micrometastases in Primary Breast Cancer: Prognostic Significance after 6 Years Follow Up. *European Journal of Cancer*. 1991; 27: 1552-5.
12. Rajarubendra N, Lawrentschuk N. Imaging of Bone Metastasis. In: Heymann D. Bone Cancer Progression and Therapeutic Approaches. London: Elsevier; 2010. 268-82.



This work is licensed under
a Creative Commons Attribution