

Penetrating brain injury from an accidental air gun shot: a case report



Sri Maliawan^{1*}, Steven Awyono², Eufрата Silvestris Junus²,
Bagus Dwiki Arya Dharma², Tjokorda Gde Bagus Mahadewa¹

ABSTRACT

Background: Air gun shot injury is a gunshot wound from a pistol or rifle that fires a bullet. The most common part of the body that penetrates in air gunshot injuries is the head, especially the orbit. The majority of fatal cases have been reported to enter that location and commonly involve children and adults. This report presents an interesting point of air gunshot injuries with brain damage surgical management.

Case Description: A 6-year-old boy got referred from other hospitals and came unconscious after being shot in the head by an air gun about eight hours before being admitted to the hospital with a range of about two meters. The patient was said to have accidentally been shot from the front of the head. The patient had a history of vomiting without a history of consciousness and seizure. On the primary survey, the airway, breathing, and circulation were clear, with a Glasgow Coma Scale (GCS) of 13. Based on the clinical examination and the result of the head CT scan, the patient was diagnosed with penetrating brain injury at the left parietal region, with multiple fragmented objects, intracerebral hemorrhage, and intraventricular hemorrhage. We then perform urgent surgery to debride and extract the bullet. There was no surgical morbidity in this patient, who was allowed to go home.

Conclusion: Penetrating brain injuries resulting from air gunshot wounds require exceptional management. Early surgery to debride the wound with consideration of bullet extraction is needed to prevent further complications and for a better outcome for the patient.

Keywords: Penetrating brain injury, air gun shot injuries, craniotomy.

Cite This Article: Maliawan, S., Awyono, S., Junus, E.S., Dharma, B.D.A., Mahadewa, T.G.B. 2023. Penetrating brain injury from an accidental air gun shot: a case report. *Bali Medical Journal* 12(2): 2228-2238. DOI: 10.15562/bmj.v12i2.4571

¹Neurosurgery Division, Department of Surgery, Faculty of Medicine, Udayana University, Prof. Dr. I.G.N.G. Ngoerah General Hospital, Bali, Indonesia

²Neurosurgery Residency Program, Faculty of Medicine, Udayana University, Prof. Dr. I.G.N.G. Ngoerah General Hospital, Bali, Indonesia

*Corresponding to:

Sri Maliawan / Neurosurgery Division, Department of Surgery, Faculty of Medicine, Udayana University, Prof. Dr. I.G.N.G. Ngoerah General Hospital, Bali, Indonesia / maliawans@yahoo.com

Received: 2023-04-17

Accepted: 2023-06-24

Published: 2023-07-20

INTRODUCTION

Air gun use compressed gas to propel a projectile, such as a ball-bearing or a bullet.¹ This gun has been used since the middle of the 16th century.² Bullet and ball-bearing guns are non-powdered bullets that may cause significant injury, especially in children and teenagers.³ An air guns-related injury is a gunshot wound from a pistol or rifle that fires a bullet. The air compression was operated by a spring or pump action mechanism or a carbon dioxide cartridge.³⁻⁵ The air guns were categorized as low-velocity missiles (<300 m/s), but they can penetrate through the abdomen, thorax, sinuses, and skull.^{6,7} These days, the new models of air guns are more powerful and capable of producing more severe damage.⁸ Most air gun shot injuries occur in children and teenagers, especially in boys, and most of them are

caused by the gun's careless use.^{6,7}

The most common part of the body that is penetrated in air gunshot injuries is the head, especially the orbit, resulting in brain injury. Most fatal cases have been reported to penetrate around that location, then disrupt major intracranial vessels, leading to severe brain injury with intracranial hemorrhage.^{1,9,10} In this case, we report an interesting case of air gunshot injuries with brain damage managed with minimally invasive bullet extraction and surgical wound debridement.

CASE PRESENTATION

We reported a case of a 6 years old boy who got referred from other hospitals and came unconscious after being shot in the head by an air gun bullet about eight hours before being admitted to the hospital with a range of about two meters. The patient

was said to have accidentally been shot by the air gun from the front of the head and then fell with his forehead first hitting the floor. There were not any seizure episodes in this patient. On examination, we found stable vital signs with a Glasgow Coma Scale (GCS) of 13, equal reactive pupil on both sides, without any local neurological deficit. We then evaluate the wound at the left parietal region (**Figure 1**). Local wound debridement already performed at the previous hospital. A skull x-ray showed a radioopaque mass with a diameter of about 1 cm on the occipital region (**Figure 2**). Later, we performed a head CT scan and found a skull fracture on the left parietal bone. The bullet penetrated through the soft tissue at the left parietal region then, causing the defect in the skull (**Figure 3**).

We then evaluate the trajectory based on the intracranial lesion and conclude that the bullet penetrated through the left

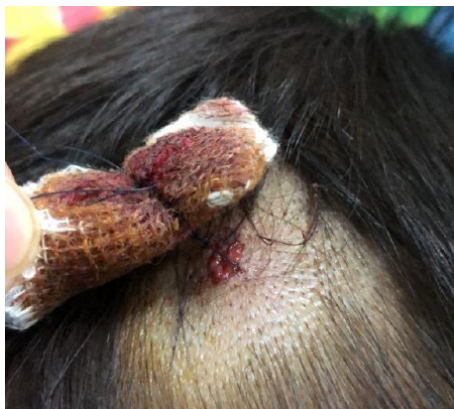

Figure 1. The bullet enters from the left parietal aspect of the head. There is no active bleeding from entering wound.

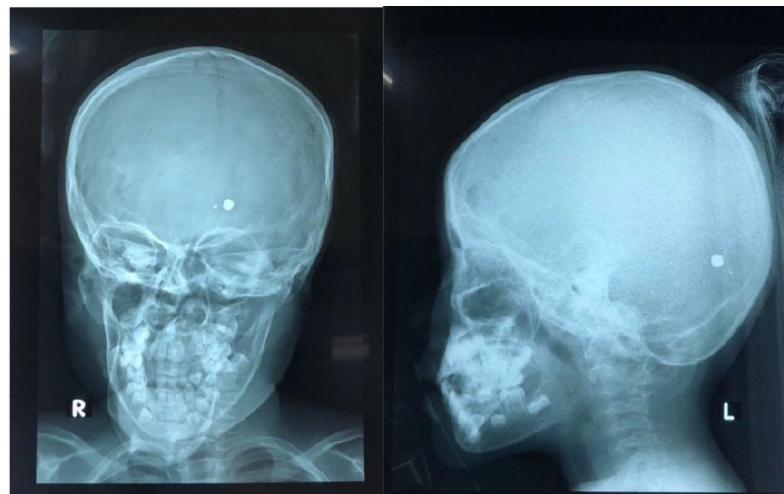

Figure 2. Ap/Lat skull X-Ray Showing the bullet was in the occipital region.

parietal lobe to the left occipital lobe with multiple hyperdense lesions through the track suggested as bone fragments.

The bullet traveled to the left occipital lobe, measuring about 9.4 cm from the entrance wound. We also found cerebral contusion along the path from the left parietal lobe to the ipsilateral occipital lobe with intraventricular hemorrhage and subarachnoid hemorrhage. Laboratory examination showed a low hemoglobin level (10,2 mg/dl), with leukocytosis (20.430 mg/dl), and slightly elevated PPT (15,9 seconds). This patient was then prepared to undergo surgical debridement with bullet extraction. Based on the CT scan, we then conclude to perform these two surgeries with different incisions (**Figure 4**).

The patient was then placed in a prone position with a neutral head position. The principle of the bullet identification was done using three-points coordinate points to minimize brain injury by using C-Arm. Careful evaluation and calculation were made to predict the depth of the bullet from the cortical area. A paramedian linear incision was made around 5 cm; a craniotomy was performed. After the dura opening, the final identification of the bullet was made with C-Arm guidance. We then perform corticotomy around 1 cm and mark our bipolar cautery on a two cm level based on our preoperative calculation. Accurate identification was made after our marking reached the cortex, and we found the bullet with the

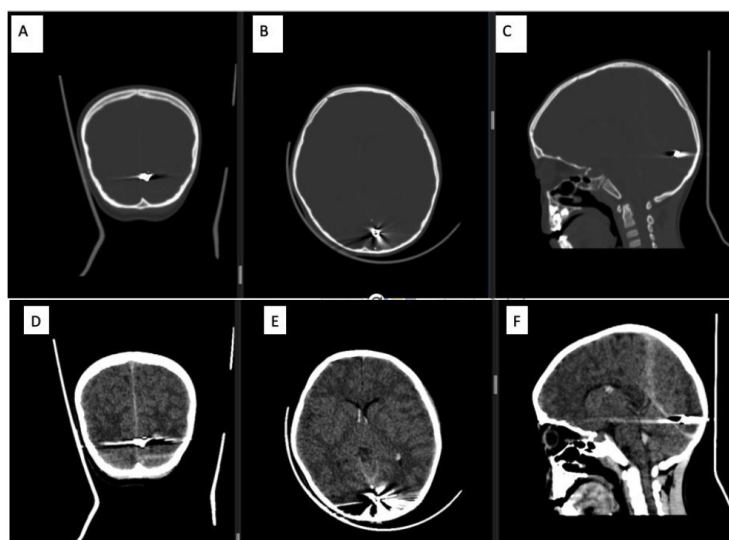


Figure 3. Head CT-Scan (A-C) Bone window and (D-F) brain window showing the bullet's trajectory from the left parietal lobe and stopped in the occipital lobe. The bullet direction was medially downward, the track left with ICH with perifocal edema, IVH, and SAH.

size around 8 mm (**Figure 5**) with perfect visualization about 2.2 cm from the cortical surface.

A linear incision was done, followed by a craniotomy over the wound to expose the damaged dura mater's border. The wound was debrided by saline irrigation with the evacuation of the superficial clot and bone fragment. After meticulous bleeding control, duraplasty was performed, and we closed the skin layer by layer.

After the surgery, he was hospitalized at the pediatric intensive care unit for three days. No blood product transfusion is needed. The postoperative evaluation showed no neurological deficit or sign of

infection. The patient was then allowed to go home after seven days of treatment at the hospital. Routine follow-up was done for his clinical presentation until six months after the surgery. There was not any history of seizures in this patient. We performed an imaging evaluation using a CT scan that showed resolution of the hemorrhage with good bone healing (**Figure 6**).

DISCUSSION

Gun-powder firearms are heavily regulated in Indonesia and not easily accessed by citizens, but a non-powder gun is still

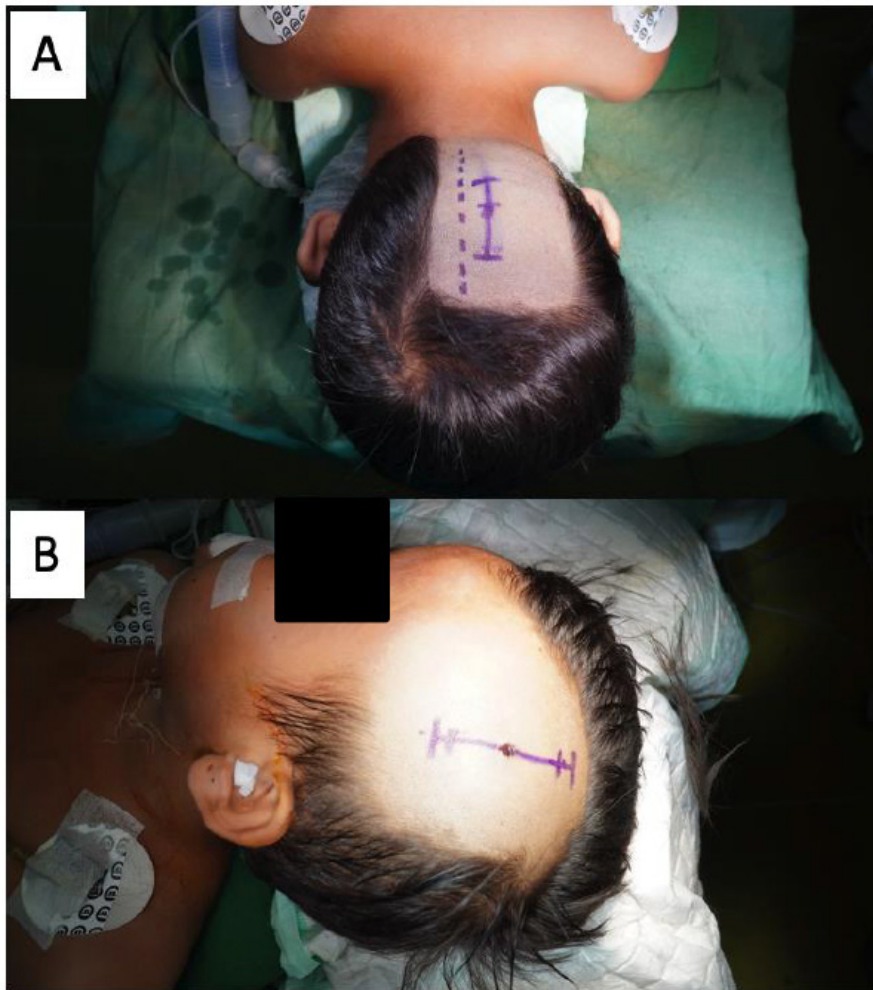


Figure 4. A) Bullet extraction procedure; patient on prone position with neutral head position. Skin incision was made based on C-arm evaluation. B) Debridement procedure; patient was positioned in supine position with head maneuver to the right to expose the wound on left parietal region.

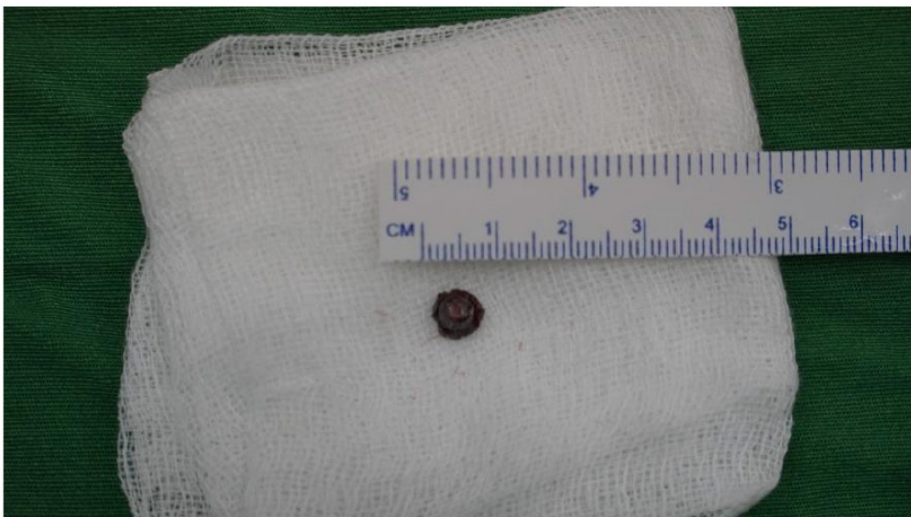


Figure 5. Bullet with the size about 8 mm after removal from intracranial.

unregulated (not controlled) by the government. This lack of regulation made non-powder guns such as air guns easily accessed by citizens and often labeled as “not a weapon” or “toy”.¹¹ Bratton et al. showed that most non-powder guns for pediatric cases were unintentional.¹² Mostly, air gunshot injuries occur in children and teenagers, especially in boys, and the gun’s careless use causes that.^{6,7} Likewise, in this case, the patient was a six-year-old boy accidentally shot with an air gun. An air gunshot penetrated the skull and led to significant brain injury. Fatal injuries commonly occur in children and adults, with the bullet entering through the eyes and forehead and penetrating the brain.^{1,9,10} Bratton et al. found that out of 49 children with air gunshot injuries on the head resulting, 38 with injuries in the eye, 10 with intracranial injuries, and 1 with a skull injury.¹²

Three of the ten children with intracranial injuries died, and two had long-term neurologic deficits. This shows that although air gunshots are grouped as low-velocity missiles, the impact caused by them may lead to fatal injury, even death. Non-fatal injuries are usually caused a significant brain injury resulting in permanent neurological deficits or blindness if it involves the orbit.¹² The possible entry of the bullets is the relatively thin skull bones, such as the temporal or squamous part of the occipital bone.¹³ In this case, the patient was shot from the front of the head with the bullet’s entry in the left parietal region, different from the common entry of the bullet. The patient also came to the hospital unconscious with a GCS of 13.

Traumatic brain injury results from the energy transferred from one object to the skull and brain. The penetrating object that penetrated the skull was divided into a non-bullet and bullet object. The non-bullet objects have less transferred energy to the brain because they have more mass, so they tend to travel slower. The bullet objects tend to have less mass, so they have more kinetic energy and higher velocities that may significantly impact the brain tissue. Factors such as muzzle velocity, impacted target mass, and transferring media may influence the bullet velocities. Penetrating and perforating brain injuries

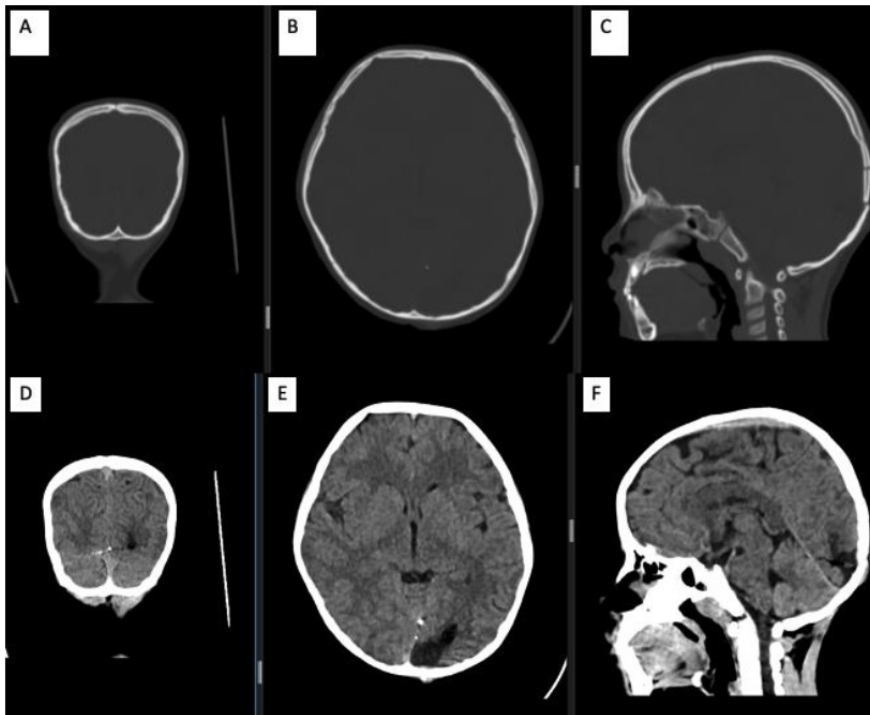


Figure 6. Head CT-Scan Brain Window showing the the bullet was completely remove from left parietal lobe. ICH with perifocal edema, IVH, and SAH was resolved.

are associated with cerebral contusions, hematomas, cerebrospinal fluid leaks, pseudoaneurysms, and arteriovenous fistula. The projectiles can penetrate the skull and ricochet off the inner aspect of the skull; this occurs most often with low-velocity shots and creates a new wound tract to the uninjured brain tissue. A projectile that travels through intracranial tissue destroys the neuronal and vascular, resulting in an immediate intracranial injury. The destruction will occur in the projectile's path and distant tissues around the path when the bullet strikes the head and transfer its kinetic energy to the extra and intracranial tissues. This mechanism will result in permanent cavitation on brain tissues directly in the projectile's path, but there are sonic waves followed by pressure waves that cause temporary cavitation. This expansion of the temporary cavities causes distant punctate hemorrhages and neuronal membrane disruption. As a result, intracranial pressure will rise as the hematoma enlarges and edema increases. Infarction also can happen due to decreases in cerebral perfusion pressure.¹⁴ Based on the CT scan in this

patient, the bullet entered through the left parietal region and penetrated through the parietal lobe. Then, the projectile path is made from the left parietal lobe to the left occipital lobe. The bullet was found at the left occipital lobe, with the length of the path ± 9.4 cm from the entrance wound. Small multiple fragmented bones were also found along the track as identified as a hyperdense lesion on the head CT. Penetrated bullet caused permanent and temporary cavitation, then disrupted the neural membrane and hemorrhaged along the projectile's path proofed by the CT scan result, which showed intracerebral hemorrhage at the left parietal lobe until the left occipital lobe with perifocal edema, and intraventricular hemorrhage at the right and left lateral ventricle, third ventricle, and fourth ventricle, and subarachnoid hemorrhage at the anterior and posterior interhemispheric fissure. This hemorrhage and edema caused an elevation of intracranial pressure in this patient.

Management of penetrating brain injury has been broadly published.¹⁵ There is still much debate over the management,

but the bullet and fragment extraction should be done if accessible. The goals are to reduce the toxicity effects and permanent neurostructural changes that can develop into permanent neurological deficits. The mass effect found on the imaging is an indication of the surgery.¹⁶ If the indication was appropriate, the intervention should be done as soon as the patient is stabilized and with a golden period under 12 hours. Debridement over 12 hours after the initial injury, there will be an increased risk of infectious complications.¹⁴ There is still debatable which technique is best to achieve the most optimal result. In the past study, there was no statistically significant advantage between craniotomy and craniectomy.¹⁷ Antibiotics may be used to prevent intracranial infections. Early surgery and debridement should be applied for cerebrospinal leakage or intracerebral hemorrhage.^{18,19} On this patient, the bullet extraction was performed by craniotomy technique to reduce the toxicity from the bullet and minimize the permanent neurologic deficits. The indication in this surgery was because there is a mass effect at the head CT-scan of the patient, and the path of the projectile can be accessed with the surgery. The craniotomy on this patient was performed using mini craniotomy, and minimal corticotomy was performed based on detailed calculation preoperatively to minimize brain injury. The evacuation of the bullet and the remnant is through the occipital. At the same time, the parietal craniotomy is used to debride the wound and extract the superficial bony fragment. A duraplasty has also been done on the patient to complete the surgical procedure. After the surgery, he was observed in the pediatric intensive care unit for about three days and then moved to the pediatric ward. During observation, he was fully conscious with stable vital sign and discharged from the hospital without any complaints or neurological deficits. The patient was scheduled for a Head CT Scan evaluation one month after the surgery.

CONCLUSION

Air gun shot injuries cause penetrating brain injury and require special care because they can lead to a fatal

manifestation. The entrance of the bullet is essential to assess which brain injury may happen in the patient. Early surgery to debride the wound is mandatory to prevent infections. If accessible, bullet extraction must be performed in order to avoid toxic effects and contamination. This procedure should be performed carefully with detailed calculations to minimize brain injury.

CONFLICT OF INTEREST

There is no competing interest regarding the manuscript.

FUNDING

This study received no funding.

ETHICS CONSIDERATION

This case study follows COPE and ICMJE protocols based on publication ethics guidelines. In addition, the informed consent for this study has been approved by the legal guardian of the patient involved in this case report.

AUTHORS CONTRIBUTION

All authors contributed equally.

REFERENCES

- Laraque D. American Academy of Pediatrics Committee on Injury, Violence, and Poison Prevention. Injury risk of nonpowder guns. *Pediatrics*. 2004;114:1357–61.
- Milroy C, Clark J, Carter N, Ruttly G, Rooney N. Air weapon fatalities. *J Clin Pathol*. 1998;51:525–9.
- Tsui C, Tsui K, Tang Y. Ball bearing (BB) gun injuries. *J Emerg Med*. 2010;17:488–91.
- Apelt N, Greenwell C, Tweed J, Notrica D, Maxson R, Garcia N, et al. Air guns: a contemporary review of injuries at six pediatric level I trauma centers. *J Surg Res*. 2020;248:1–6.
- Kiran D, Mittal S. Gunshot (pellets) injury to the maxillofacial complex: a case report. *Chinese J Traumatol*. 2014;17(3):170–2.
- Wijaya A, Ayusta I, Niryana I. Air gun wound: bihemispheric penetrating brain injury in a paediatric patient. *BJR Case Rep*. 2019;5(2):20180070.
- Klopotek B, Weibley R, Chapados R. Air rifles are more than toys: BB gun-related traumatic brain injury. *Pediatr Ann*. 2014;43(12):494–6.
- Miner M, Cabrera J, Ford E. Intracranial penetration due to BB air rifle injuries. *Neurosurgery*. 1986;19:952–4.
- Nguyen M, Annest J, Mercy J, Ryan G, Fingerhut L. Trends in BB/pellet gun injuries in children and teenagers in the United States, 1985–99. *Inj Prev*. 2002;8(3):185–91.
- Ceylan H, McGowan A, Stringer M. Air weapon injuries: a serious and persistent problem. *Arch Dis Child*. 2002;86(4):234–5.
- Rahmatullah MI, Parenrengi MA, Suryaningtyas W. Unintentional penetrating brain injuries caused by air rifles in teenagers: Two case report. *Interdiscip Neurosurg Adv Tech Case Manag*. 2021;25:101203.
- Bratton SL, Dowd MD, Brogan T V, Hegenbarth MA. Serious and fatal air gun injuries: more than meets the eye. *Pediatrics*. 1997;100(4):609–12.
- Martinez-Lage J, Mesones J, Gilabert A. Air-gun pellet injuries to the head and neck in children. *Pediatr Surg Int*. 2001;17:657–60.
- Van Wyck DW, Grant GA. Penetrating traumatic brain injury: a review of current evaluation and management concepts. *J Neurol Neurophysiol*. 2015;6(6):1000336.
- Syrmos N, Ganau M, De Carlo A, Prisco L, Ganau L, Valadakis V, et al. Dealing with the surgical and medical challenges of penetrating brain injuries. *Case Rep Surg*. 2013;2013:1–4.
- Alvis-Miranda HR, Adie Villafaña R, Rojas A, Alcalá-Cerra G, Moscote-Salazar LR. Management of craniocerebral gunshot injuries: a review. *Korean J Neurotrauma*. 2015;11(2):35.
- Kazim SF, Shamim MS, Tahir MZ, Enam SA, Waheed S. Management of penetrating brain injury. *J Emergencies, Trauma Shock*. 2011;4(3):395–402.
- Amirjamshidi A, Abbassioun K. Air-gun pellet injuries to the head and neck: what are the mechanisms of injury and optimal steps in management? *J Neurosurg Pediatr*. 2016;18:507–10.
- Gondowardojo YRB, Argie D, Adam A, Ratnasari NLMN. Clinical, radiological features, and surgical management of spontaneous intracerebral hemorrhage patients in East Nusa Tenggara-Indonesia. *Bali Med J*. 2018;7(2):426–30.



This work is licensed under a Creative Commons Attribution