

## A success story of modified Sugiura technique surgery in a non-cirrhotic portal hypertension (NCPH)

Aditya Satrio Faredisto<sup>1\*</sup>, Budi Widodo<sup>2</sup>

### ABSTRACT

**Background:** Non-cirrhotic portal hypertension refers to elevated portal vein pressure in the absence of liver cirrhosis. Surgery could be an effective procedure for patients with recurrent variceal bleeding who fail to respond to pharmacotherapy or endoscopic therapy. We report a success story of modified Sugiura technique in managing a patient with non-cirrhotic portal hypertension.

**Case presentation:** A male, 24-year-old, complained of recurrent vomiting of dark red blood color for six months. Anemic conjunctiva and splenomegaly were discovered during a physical examination. Pancytopenia and normal hepatobiliary function were revealed in the laboratory examination. Ultrasonography of the abdomen demonstrates nonspecific splenomegaly. An abdominal computerized tomography scan revealed hepatosplenomegaly and pelvic fluid accumulations. Grade IV esophageal varices and mild portal hypertensive gastropathy were observed during endoscopic examination. Active bleeding still presented despite initiation of medical treatment and endoscopic ligation. Finally, a surgical procedure using the Sugiura technique was performed. The patient was recovered, no recurrent symptom of hematemesis was reported after one year of follow-up.

**Conclusion:** Modified Sugiura technique is a useful treatment of choice in non-cirrhotic portal hypertension patients who failed to respond other medical treatments. However, comprehensive assessment is critical prior to choose this procedure.

**Keywords:** Non-cirrhotic portal hypertension, NCPH, modified Sugiura technique, portal hypertension.

**Cite This Article:** Faredisto, A.S., Widodo, B. 2022. A success story of modified Sugiura technique surgery in a non-cirrhotic portal hypertension (NCPH). *Bali Medical Journal* 11(3): 1828-1833. DOI: 10.15562/bmj.v11i3.3848

<sup>1</sup>Department of Internal Medicine, Faculty of Medicine, Universitas Airlangga - Dr. Soetomo General Academic Hospital, Surabaya, 60132, Indonesia;

<sup>2</sup>Division of Gastroenterohepatology, Department of Internal Medicine, Faculty of Medicine, Universitas Airlangga - Dr. Soetomo General Academic Hospital, Surabaya, 60132, Indonesia;

\*Corresponding author:  
Aditya Satrio Faredisto;  
Department of Internal Medicine, Faculty of Medicine, Universitas Airlangga - Dr. Soetomo General Academic Hospital, Surabaya, 60132, Indonesia;  
aditfaredisto@gmail.com

Received: 2022-10-18

Accepted: 2022-11-12

Published: 2022-11-30

### INTRODUCTION

Non-cirrhotic portal hypertension (NCPH) refers to elevated portal vein pressure in the absence of liver cirrhosis. The causes of NCPH can be categorized as prehepatic, intrahepatic, and posthepatic. In prehepatic and posthepatic NCPH, the disruptions of the vascular system do not involve the liver parenchyma. When involving the liver parenchyma (intrahepatic cause), it is further divided into presinusoidal, sinusoidal, or post-sinusoidal origin.<sup>1</sup>

The incidence of NCPH varies worldwide. From 1980 to 1990, 23% of portal hypertension cases in India and 14-27% of portal hypertension cases in Western countries, were identified as NCPH.<sup>2</sup> There were no differences in NCPH incidents among different ages or gender. In Eastern countries, NCPH is associated with low socioeconomic status. For an unknown reasons, differences in

socioeconomic status, environmental conditions, exposure to pathogens, average life expectancy, and ethnicity play essential roles in the development of NCPH.<sup>2,3</sup> In Japan, decreasing NCPH incidence in the last decades was associated with improved hygiene and better living standards.<sup>3</sup>

The treatment in patients with NCPH is focused on preventing and treating variceal hemorrhage and managing portal hypertension. Other managements include discontinuation of medications associated with NCPH and managing related medical conditions.<sup>2,4</sup> Management of cirrhotic portal hypertension applied in NCPH patients results in similar outcomes.<sup>4</sup> Primary and secondary prevention of variceal bleeding, including nonselective beta-blockers, endoscopic variceal ligation, and surgical approach. Surgery is an effective procedure for patients with recurrent variceal bleeding who fail to respond to pharmacotherapy or endoscopic therapy (ligase and

sclerotherapy).<sup>2-5</sup> NCPH is one of the main problems in gastroenterohepatology together with other diseases.<sup>5,6</sup> Surgery that can be done is either using transjugular intrahepatic portosystemic shunt (TIPS) or non-shunting procedure using modified Sugiura technique.<sup>4</sup>

In this case report, we report a success of a modified Sugiura technique in a NCPH patient who was previously unable to improve by pharmacotherapies and endoscopic ligation.

### CASE PRESENTATION

A male, 24-year-old, was referred to Dr. Soetomo Hospital Surabaya, Indonesia with hematemesis. The patient vomited twice with a volume of 200-300 mL of dark red blood color. The previous medical history shows hematemesis has occurred in the last six months. The patient also complained of lethargy. No black, tarry stool was reported.

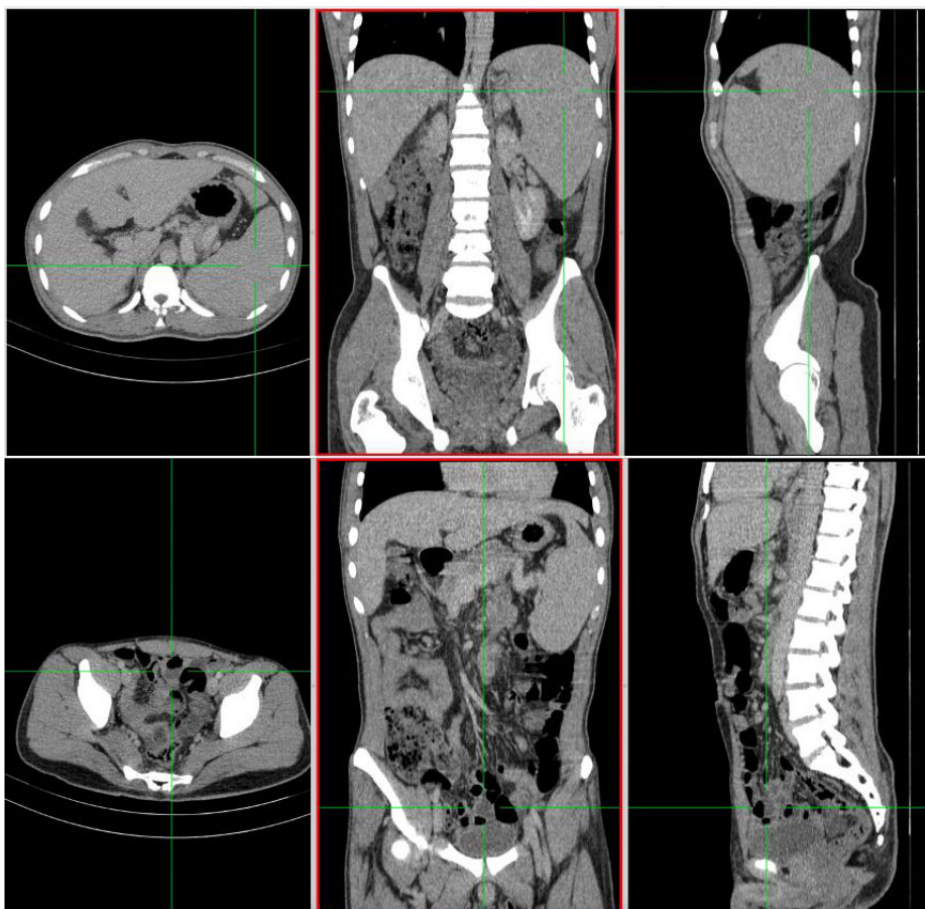
The patient was repeatedly hospitalized at a nearby hospital for the same complaints. From the last admission, the patient received a blood transfusion. No history of alcohol, smoking, or previous illness such as recurrent fever, diabetes mellitus, or cardiovascular disease.

On physical examination, the patient was *compos mentis* GCS 4/5, blood pressure of 106/60 mmHg, heart rate was 101 x/min regular, strong pulse adequate content, respiratory rate was 21 x/min, the axillary temperature was 37.1°C, and SpO<sub>2</sub> was 98% of free air. The conjunctiva was anemic but there was no jaundice. No abnormality was found on thorax examination. On abdominal examination, there was a normal bowel sound and tympanic percussion. The liver was not palpable. There was spleen enlargement of Schaffner I and Hackett II. The extremities were warm and dry with capillary refill time less than two seconds. No edema was found on both legs.

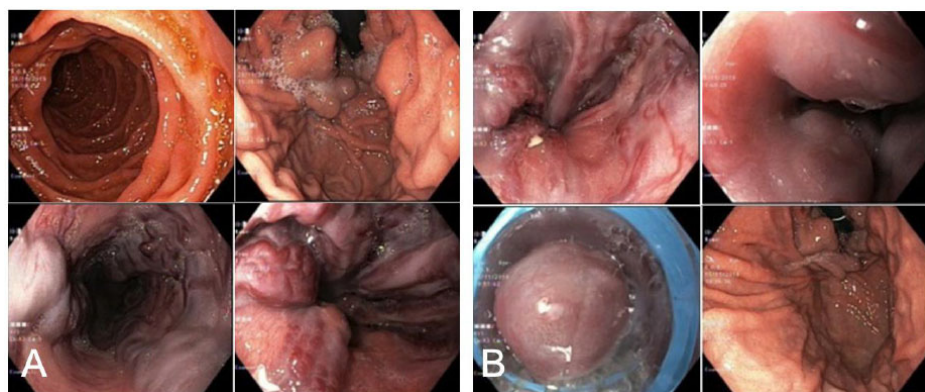
Laboratory tests were significant for hypochromic microcytic anemia (hemoglobin 4.1 g/dL, hematocrit 12.6%, MCV 77.6, and MCH 24.1), lymphopenia (leukocytes 9.300 mm<sup>3</sup>), and thrombocytopenia (platelets 156.000/mm<sup>3</sup>). Other examinations were as follows: PTT 11.2 s, APTT 25.9 s, ALT 27 U/L, AST 26 U/L, albumin 2.8 mg/dL, BUN 22 mg/dL, serum creatinine 0.5 mg/dL, sodium 144 mEq/L, potassium 4.5 mEq/L and chloride 110 mEq/L. Both HBsAg and anti-HCV were non-reactive. Peripheral blood analysis showed hypochromic erythrocytes, microcytic, anisopoikilocytosis, polychromasia cells (+), decreased leukocyte count, dominated by segment neutrophils; decreased platelet count, and giant platelet (+). These findings suggest pancytopenia.

Abdominal ultrasonography showed nonspecific splenomegaly. Abdominal computerized tomography (CT)-scan showed hepatosplenomegaly (Figure 1). Portal venous thrombus was not visible, portal vein diameter of ±1.2 cm (normal <1.3 cm), and linealis vein of ±1.1 cm (normal <1 cm), and fluid accumulation in the pelvic cavity (Figure 1).

Endoscopic examination revealed grade IV esophageal varices, red color spot (RCS) (+++), type I gastroesophageal



**Figure 1.** Abdominal CT scan demonstrated hepatosplenomegaly and pelvic fluid accumulations.

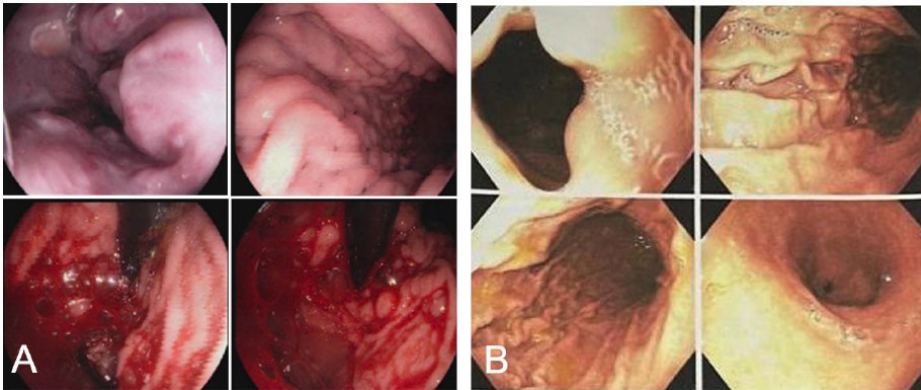


**Figure 2.** Endoscopic examination on admission revealed grade IV esophageal varices (A) and after variceal ligation procedure (B).

varices (GOV-1), and mild portal hypertensive gastropathy (Figure 2A). Transient elastography (fibroscan) showed a median of 4.3 kPa, which does not suggest liver fibrosis.

The patient was diagnosed with hematemesis, rupture of esophageal varices caused by NCPH. The patient was fasted, a nasogastric tube was inserted, and the patient was given IV octreotide

200 mcg every 8 h, lactulose syrup 10 gram every 8 h. and sucralfate syrup 15 ccs every 8 h and planned for packed red cells (PRC) transfusion 500mL/day until the hemoglobin was above 8 g/dL. The patient also underwent variceal ligation (Figure 2B). The patient was discharged and was ordered to control at outpatient clinic routinely.



**Figure 3.** Endoscopic examination one-month follow-up after initial endoscopic ligation shows recurrent active bleeding (A) and after three months post-surgery shows esophageal grade II varices, GOV-1, mild portal hypertensive gastropathy and no recurrent bleeding (B).

On one month follow-up after initial endoscopic ligation, follow-up endoscopic examination revealed grade III esophageal varices II, RCS (+). Active bleeding can still be seen (Figure 3A). The patient was readmitted, and was consulted to the Department of Digestive Surgery. Surgical with Sugiura procedure was performed. After the procedure, there were no recurrent symptoms of hematemesis. The endoscopy was performed with results of esophageal grade II varices, RCS (+++), GOV-1, mild portal hypertensive gastropathy. The symptoms were improved, and after one week of observation the patient was discharged from the hospital without recurrent sign and symptoms of variceal bleeding.

On one month follow-up after surgery, there was no complaint. Laboratory tests were: hemoglobin 10.7 g/dL, hematocrit 34.2%, MCV 77.7, MCH 24.3, normal leukocytes  $6.230 \text{ mm}^3$ , normal platelets ( $404.000/\text{mm}^3$ ), and normal hemostatic parameters (PTT 9.3 s and APTT 22.8 s). Other examinations were as follows: increased in liver function (ALT 70 U/L and AST 103 U/L), albumin 3.6 mg/dL, BUN 11.0 mg/dL, serum creatinine 0.82 mg/dL, sodium 135 mEq/L, potassium 3.7 mEq/L and chloride 101 mEq/L.

Three months follow-up after surgery, the patient had no complaint related to variceal bleeding. Laboratory examination revealed improvement pancytopenia (hemoglobin 10.7 g/dL, platelets  $404 \times 10^3/\text{UL}$ , WBC  $6.3 \times 10^3/\text{UL}$ ) and normal hemostatic parameters (PTT 9.3 s and

APTT 22.8 s). Other examinations were as follows: ALT 70 U/L, AST 103 U/L, albumin 3.6, BUN 11.0, serum creatinine 0.82, sodium 135 mEq/L, potassium 3.7 mEq/L and chloride 101 mEq/L. Endoscopic examination revealed esophageal grade II varices, RCS (-), GOV-1, and mild portal hypertensive gastropathy (Figure 3B). One year after surgery, no recurrent variceal bleeding was found.

## DISCUSSION

In the absence of liver cirrhosis, portal hypertension can be caused by a wide range of conditions and is defined as NCPH. Idiopathic NCPH (INCPH) is characterized by the signs of portal hypertension without evidence of cirrhosis or extrahepatic portal vein obstruction on liver biopsy. Other causes of chronic liver disease and other etiologies leading to NCPH should be excluded. Diagnosis of idiopathic NCPH requires several criteria, including: (1) at least one sign of portal hypertension which includes splenomegaly/hypersplenism and symptoms of portal hypertension, gastric or esophageal varices, ascites, or collateral veins; (2) exclusion of cirrhosis obtained from liver biopsy; (3) exclusion of chronic liver diseases such as hepatitis B and C infection or other diseases; and (5) radiologic examination of patent hepatic vein.<sup>1</sup>

The exact cause of NCPH is unknown. Several proposed underlying mechanisms including chronic or recurrent infections, exposure to drugs and toxins

(azathioprine and other cytotoxic drugs), immunological disorders, genetic disorders, and hypercoagulability. Repeated episodes of umbilical sepsis, bacterial infection, and diarrhea in childhood (often in low socioeconomic status) can lead to portal pyemia and pylephlebitis, leading to vascular endothelial damage, microthrombosis, sclerosis, and obstruction of the portal vein. These underlying mechanisms result in the development of NCPH in young adults. HIV infection can cause variceal bleeding associated with HIV or as the long-term effects of antiretroviral drugs such as didanosine.<sup>7</sup> Impaired immune response and genetic factors that cause NCPH are still not clearly understood. A study found different anti-DNA antibodies in 65% of Japanese citizens with NCPH.<sup>8</sup> High frequency of HLA-DR3 was also reported in some NCPH patients.<sup>9</sup>

The signs and symptoms of patients with NCPH are related to the complications of portal hypertension. Liver function in these patients is usually preserved. As shown in our patient, recurrent variceal bleeding is the most common clinical manifestation. Almost 70% of patients with the INCPH have esophageal varices at presentation; in a third of them, esophageal variceal bleeding is the first manifestation of the disease. The prognosis of variceal bleeding in NCPH is better than cirrhotic patients due to preserved liver function compared to those with cirrhosis.<sup>10</sup> Recent research shows that within one year, the chance of developing small varicose veins is 10% and is 13% in large varicose veins, a similar rate to cirrhotic patients. The probability of first variceal bleeding was 9%, and the probability of rebleeding in 1 year, despite secondary prophylaxis (beta-blockers and endoscopic ligation), was 22%.<sup>2</sup>

Ascites are present in 50% of cases and are associated with certain comorbidities such as variceal bleeding or infection.<sup>11,12</sup> In general, ascites are easily controlled with low-dose diuretics and treating the causative factors (varicose veins and infections). Hepatic encephalopathy is a rare complication and is associated with precipitating factors. There are several reports of hepatopulmonary syndrome, hepatopulmonary hypertension and hepatocellular carcinoma. Ninety-

five percent of NCPH patients had splenomegaly and left upper quadrant pain.<sup>12</sup> Portal vein thrombosis is also frequently found in patients with NCPH, with prevalence varying between 13-46%. Recent studies have found a 9% chance of developing portal vein thrombosis each year. HIV infection and variceal bleeding at diagnosis have been described as independent factors associated with a high risk of portal vein thrombosis. Most patients are usually asymptomatic at diagnosis, but it is crucial to screen for portal vein thrombosis in NCPH patients.<sup>13</sup> In our patient, ascites were discovered on CT scan examination, where it revealed fluid accumulation in the pelvic cavity.

On physical examination, our patient had spleen enlargement. Hypersplenism is present in 27% to 87% of patients. Hypersplenism also manifests into laboratory examination, the commonest being anemia followed by thrombocytopenia and leukopenia (pancytopenia).<sup>14</sup> As in our patient, pancytopenia and normal liver enzyme were detected. Pancytopenia later improved after the patient underwent the Sugiura procedure.

In our patient, ultrasonography and CT-scan revealed hepatosplenomegaly and pelvic fluid accumulation, however we did not perform liver biopsy. Abdominal ultrasonography is typically used to perform the initial assessment in patients with abnormal liver test results or detected esophageal varices. Sonographic features of INCPH can include nodularity of the liver surface and thickening of the portal vein walls. These manifestations, however, are not specific and can be seen in patients with liver cirrhosis.<sup>1,15</sup> MRI and CT-scan mainly revealed an enlarged caudate lobe, nonnodular liver, atrophic right lobe, and preserved liver volume. Liver biopsy is considered necessary to clarify the cause of portal hypertension. It is seldom performed due to the high risk of bleeding.<sup>16,17</sup>

In our patient, the transient elastography showed a median LS of 4.3 kPa. Liver stiffness measurement by transient elastography is a non-invasive method used for fibrosis diagnosis in chronic liver diseases. The presence of low liver stiffness (<10 kPa) in patients

with clinically evident portal hypertension may exclude liver cirrhosis diagnosis.<sup>18</sup> In a study, the median hepatic venous pressure gradient in NCPH patients was 5.02–10 mmHg, and LS of  $6.6 \pm 2.7$  kPa.<sup>19</sup> On endoscopic examination, our patient revealed grade IV esophageal varices GOV-1, and mild portal hypertensive gastropathy at admission. Esophageal varices of NCPH patient are seen in 80-90% of NCPH.<sup>20</sup>

The focus of management in NCPH patients is prevention and treatment of variceal bleeding using vasoactive drugs, endoscopic bleeding control, blood replacement with transfusion, and prophylactic antibiotics. Usually, NCPH patients treated the same as cirrhotic patients with portal hypertension.<sup>17</sup> Several studies have reported that the long-term outcomes obtained in patients treated using cirrhotic varicose veins treatment guidelines have favorable results when applied to patients with NCPH. Discontinuation of drugs associated with the development of NCPH is also essential. Biochemical and histologically reversible improvement and function were found in patients discontinuing azathioprine in patients receiving liver transplantation.<sup>21</sup>

In ongoing bleeding, the patient must be fasted immediately and receive nasogastric tube insertion followed by gastric lavage. These are necessary to remove fresh blood or clots from the stomach and prepare for diagnostic and therapeutic endoscopic procedures. Prokinetic agents such as erythromycin can be given to improve visualization during endoscopy.<sup>22</sup> Patients with active bleeding and hypovolemia often require red blood cells and platelets transfusion. The administration of prohemostatic agents (fresh frozen plasma, prothrombin complex concentrate, recombinant factor VIIa) was not proven to provide any benefit. Red blood cell transfusion is given if the hemoglobin level is below 7g/dL with a hemoglobin target of 7–9 g/dL. However, in patients with increased risk of side effects of long-term anemia (such as unstable artery coronary disease or active bleeding), the hemoglobin target may be above 9 g/dL. Intravascular volume status should be monitored to prevent volume overload because portal hypertension

rebound can induce rebleeding. Platelet transfusions are needed if the platelet count is below  $50,000/\mu$ .<sup>23</sup> Anticoagulants cannot be used to prevent portal vein thrombosis but may be an option in patients with hypercoagulable disorders.<sup>10</sup> Prophylactic antibiotics can be given prior to endoscopy. The antibiotic of choice is a broad spectrum, such as IV ceftriaxone 1 g daily for seven days. If a patient discontinues treatment before seven days with intravenous antibiotics, the oral ciprofloxacin 500 mg every 12 h can be substituted for a total of seven days of antibiotics.<sup>24</sup> Our patient was fasted, and received nasogastric tube insertion and red blood cell transfusion. The patient also received an IV bolus of octreotide on admission before endoscopic intervention.

Primary and secondary prevention of variceal bleeding, including non-selective beta-blockers and endoscopic variceal ligation. Data from several cohort studies suggest that the management of cirrhotic portal hypertension can be applied to patients with NCPH and provide similar outcomes.<sup>25</sup> Transjugular intrahepatic portosystemic shunt (TIPS) is an effective therapy that can be given to patients who fail or do not respond to medical or endoscopic therapy.<sup>26</sup> Portosystemic shunt surgery is an effective alternative for patients who fail endoscopic therapy, although it has now been replaced with TIPS.<sup>27</sup> Splenectomy may be performed in patients with symptomatic hypersplenism (recurrent bleeding, severe anemia requiring large transfusions, or recurrent splenic infarction).<sup>28</sup> Liver transplantation can be performed with the same indications as end-stage liver cirrhosis patients. However, liver transplantation in patients with NCPH needs further investigation.<sup>29</sup> In our patient, endoscopic variceal ligation was performed, however, there was recurrent active bleeding indicating the need of other interventions.

Another option is the Sugiura procedure. Sugiura procedure is a non-shunting procedure first performed by Sugiura and Futagawa in 1973. Initially, this procedure was not widely accepted due to complex procedure and high postoperative mortality rate. However, in the late 1980s, the modified Sugiura procedure began to be widely accepted

and is effective in controlling esophageal variceal bleeding. Recently, TIPS had replaced the Sugiura procedure in the majority of the cases.

The Sugiura procedure has low operative mortality and low long-term rebleeding rate. Sugiura procedure consists of transthoracic esophageal gastric devascularization, including splenectomy.<sup>30,31</sup> In recent years, the modified Sugiura procedure has been performed as the initial treatment in patients with end-stage liver disease awaiting liver transplantation. The modified Sugiura technique is a one-stage transabdominal approach that is used to achieve extensive gastroesophageal devascularization.<sup>32,33</sup> The total operation time is an average of 5 h. In patients with cirrhosis, Sugiura procedure result in a lower incidence of postoperative encephalopathy and better quality of life with prolonged survival compared to TIPS.<sup>34</sup> The report of Sugiura procedure performed on NCPH patients is limited, and in our patient, this procedure results favorable clinical improvement in a NCPH patient that was refractory to medical treatment and endoscopic ligation.

## CONCLUSION

We reported a 24-year-old male patient with NCPH underwent a Sugiura procedure. The patient complained of hematemesis that occurred in the last six months. Ultrasound and abdominal CT-scan revealed hepatosplenomegaly. No fibrosis was found on the transient elastography examination. Endoscopy revealed esophageal varices and mild portal hypertensive gastropathy. The patient has been treated for primary and secondary prevention using beta-blocker drugs and endoscopic ligation, but the symptoms recurred. The patient underwent the modified Sugiura procedure and no recurrent bleeding was reported up to 1-year post-surgical follow-up.

## ETHICAL APPROVAL

Written informed consent for this case report was obtained from the patient for publication.

## COMPETING INTERESTS

The authors have no conflicts of interest to declare.

## GRANT INFORMATION

There are no funding sources to report.

## AUTHOR CONTRIBUTIONS

ASF was responsible in concepting and designing the study, conducting and obtaining the clinical data, and preparing the manuscript. BW was responsible in concepting and designing the study, supervising the study and revising the manuscript.

## REFERENCES

- Schouten JNL, Garcia-Pagan JC, Valla DC, Janssen HLA. Idiopathic noncirrhotic portal hypertension. *Hepatology* [Internet]. 2011;54(3):1071–81. Available from: <http://dx.doi.org/10.1002/hep.24422>
- Khanna R, Sarin SK. Non-cirrhotic portal hypertension – Diagnosis and management. *J Hepatol* [Internet]. 2014;60(2):421–41. Available from: <http://dx.doi.org/10.1016/j.jhep.2013.08.013>
- Schouten JNL, Verheij J, Seijo S. Idiopathic non-cirrhotic portal hypertension: a review. *Orphanet J Rare Dis* [Internet]. 2015;10(1). Available from: <http://dx.doi.org/10.1186/s13023-015-0288-8>
- Siramolpiwat S, Seijo S, Miquel R, Berzigotti A, Garcia-Criado A, Darnell A, et al. Idiopathic portal hypertension: Natural history and long-term outcome. *Hepatology* [Internet]. 2014;59(6):2276–85. Available from: <http://dx.doi.org/10.1002/hep.26904>
- Enggar S, Widodo B. Gastrointestinal bleeding as a life-threatening complication of liver abnormality in a Turner syndrome patient. *Bali Medical Journal*. 2022;11(1):246-9. Available from: DOI: <https://doi.org/10.15562/bmj.v11i1.3259>
- Juniawan RFD, Maimunah U, Sugihartono T, Kholili U, Widodo B, Thamrin H, et al. Complications of repeated percutaneous transhepatic biliary drainage (PTBD) for palliation of obstructive jaundice in cholangiocarcinoma patient. *Bali Medical Journal*. 2022;11(2):850-5. Available from: DOI: <https://doi.org/10.15562/bmj.v11i2.3465>
- Kovari H, Ledergerber B, Peter U, Flepp M, Jost J, Schmid P, et al. Association of Noncirrhotic Portal Hypertension in HIV-Infected Persons and Antiretroviral Therapy with Didanosine: A Nested Case-Control Study. *Clin Infect Dis* [Internet]. 2009;49(4):626–35. Available from: <http://dx.doi.org/10.1086/603559>
- Pulvirenti F, Pentassuglio I, Milito C, Valente M, De Santis A, Conti V, et al. Idiopathic Non Cirrhotic Portal Hypertension and Spleno-Portal Axis Abnormalities in Patients with Severe Primary Antibody Deficiencies. *J Immunol Res* [Internet]. 2014;2014:1–8. Available from: <http://dx.doi.org/10.1155/2014/672458>
- Vilarinho S, Sari S, Yilmaz G, Stiegler AL, Boggon TJ, Jain D, et al. Recurrent recessive mutation in deoxyguanosine kinase causes idiopathic noncirrhotic portal hypertension. *Hepatology* [Internet]. 2016;63(6):1977–86. Available from: <http://dx.doi.org/10.1002/hep.28499>
- Hernández-Gea V, Baiges A, Turon F, Garcia-Pagan JC. Idiopathic Portal Hypertension. *Hepatology* [Internet]. 2018;68(6):2413–23. Available from: <http://dx.doi.org/10.1002/hep.30132>
- Medisika Hertiti D, Boedi Setiawan P, Ichsan Prabowo G. The Correlation Between The Severity Of Liver Cirrhosis With Esophageal Varices In Rsd Dr Soetomo Surabaya. *Curr Intern Med Res Pract Surabaya J* [Internet]. 2022;3(2):36–9. Available from: <http://dx.doi.org/10.20473/cimrj.v3i2.38065>
- Schouten JNL, Nevens F, Hansen B, Laleman W, den Born M, Komuta M, et al. Idiopathic noncirrhotic portal hypertension is associated with poor survival: results of a long-term cohort study. *Aliment Pharmacol & Ther* [Internet]. 2012;35(12):1424–33. Available from: <http://dx.doi.org/10.1111/j.1365-2036.2012.05112.x>
- Hillaire S, Bonte E, Denninger MH, Casadevall N, Cadranet JF, Lebrec D, et al. Idiopathic non-cirrhotic intrahepatic portal hypertension in the West: a re-evaluation in 28 patients. *Gut* [Internet]. 2002;51(2):275–80. Available from: <http://dx.doi.org/10.1136/gut.51.2.275>
- Khanna R, Sarin SK. Noncirrhotic Portal Hypertension. *Clin Liver Dis* [Internet]. 2019;23(4):781–807. Available from: <http://dx.doi.org/10.1016/j.cld.2019.07.006>
- Sigma SHA. The Effect and Mechanism of Sucrose Consumption to Liver Disease – A Systematic Literature Review. *Biomol Heal Sci J* [Internet]. 2022;5(1):47–53. Available from: <http://dx.doi.org/10.20473/bhsj.v5i1.35160>
- Zhao ZL, Wei Y, Wang TL, Peng LL, Li Y, Yu MA. Imaging and Pathological Features of Idiopathic Portal Hypertension and Differential Diagnosis from Liver Cirrhosis. *Sci Rep* [Internet]. 2020;10(1). Available from: <http://dx.doi.org/10.1038/s41598-020-59286-8>
- Saputri JH, Widodo B. Histoacryl Glue Injection for Treatment in Patient with Gastric Varices Non-cirrhotic Portal Hypertension. *Indones J Gastroenterol Hepatol Dig Endosc* [Internet]. 2020;19(3):185–9. Available from: <http://dx.doi.org/10.24871/1932018185-189>
- Gioia S, Nardelli S, Ridola L, Riggio O. Causes and Management of Non-cirrhotic Portal Hypertension. *Curr Gastroenterol Rep* [Internet]. 2020;22(12). Available from: <http://dx.doi.org/10.1007/s11894-020-00792-0>
- Sharma P, Agarwal R, Dhawan S, Bansal N, Singla V, Kumar A, et al. Transient Elastography (Fibroscan) in Patients with Non-cirrhotic Portal Fibrosis. *J Clin Exp Hepatol* [Internet].

- 2017;7(3):230–4. Available from: <http://dx.doi.org/10.1016/j.jceh.2017.03.002>
20. Enyüz OF, Yeşildag E, Emir H, Tekant G, Yeker Y, Bozkurt P. Sugiura procedure in portal hypertensive children. *J Hepatobiliary Pancreat Surg*. 2001;8(3):245–9. Available from doi: [10.1007/s005340170024](https://doi.org/10.1007/s005340170024).
  21. Sarin SK, Gupta N, Jha SK, Agrawal A, Mishra SR, Sharma BC, et al. Equal Efficacy of Endoscopic Variceal Ligation and Propranolol in Preventing Variceal Bleeding in Patients With Noncirrhotic Portal Hypertension. *Gastroenterology* [Internet]. 2010;139(4):1238–1245.e1. Available from: <http://dx.doi.org/10.1053/j.gastro.2010.06.017>
  22. Altraif I, Handoo FA, Aljumah A, Alalwan A, Dafalla M, Saeed AM, et al. Effect of erythromycin before endoscopy in patients presenting with variceal bleeding: a prospective, randomized, double-blind, placebo-controlled trial. *Gastrointest Endosc* [Internet]. 2011;73(2):245–50. Available from: <http://dx.doi.org/10.1016/j.gie.2010.09.043>
  23. Cerqueira RM, Andrade L, Correia MR, Fernandes CD, Manso MC. Risk factors for in-hospital mortality in cirrhotic patients with oesophageal variceal bleeding. *Eur J Gastroenterol & Hepatol* [Internet]. 2012;24(5):551–7. Available from: <http://dx.doi.org/10.1097/meg.0b013e3283510448>
  24. Chavez-Tapia NC, Barrientos-Gutierrez T, Tellez-Avila F, Soares-Weiser K, Mendez-Sanchez N, Gluud C, et al. Meta-analysis: antibiotic prophylaxis for cirrhotic patients with upper gastrointestinal bleeding - an updated Cochrane review. *Aliment Pharmacol & Ther* [Internet]. 2011;34(5):509–18. Available from: <http://dx.doi.org/10.1111/j.1365-2036.2011.04746.x>
  25. Noronha Ferreira C, Seijo S, Plessier A, Silva-Junior G, Turon F, Rautou PE, et al. Natural history and management of esophagogastric varices in chronic noncirrhotic, nontumoral portal vein thrombosis. *Hepatology* [Internet]. 2016;63(5):1640–50. Available from: <http://dx.doi.org/10.1002/hep.28466>
  26. Bissonnette J, Garcia-Pagán JC, Albillos A, Turon F, Ferreira C, Tellez L, et al. Role of the transjugular intrahepatic portosystemic shunt in the management of severe complications of portal hypertension in idiopathic noncirrhotic portal hypertension. *Hepatology* [Internet]. 2016;64(1):224–31. Available from: <http://dx.doi.org/10.1002/hep.28547>
  27. Karagul S, Yagci MA, Tardu A, Ertugrul I, Kirmizi S, Sumer F, et al. Portosystemic Shunt Surgery in Patients with Idiopathic Noncirrhotic Portal Hypertension. *Ann Transplant* [Internet]. 2016;21:317–20. Available from: <http://dx.doi.org/10.12659/aot.898253>
  28. Sarin Sk, Kapoor D. Non-cirrhotic portal fibrosis: Current concepts and management. *J Gastroenterol Hepatol* [Internet]. 2002;17(5):526–34. Available from: <http://dx.doi.org/10.1046/j.1440-1746.2002.02764.x>
  29. Krasinskas AM, Eghtesad B, Kamath PS, Demetris AJ, Abraham SC. Liver transplantation for severe intrahepatic noncirrhotic portal hypertension. *Liver Transplant* [Internet]. 2005;11(6):627–34. Available from: <http://dx.doi.org/10.1002/lt.20431>
  30. Sugiura M. Further Evaluation of the Sugiura Procedure in the Treatment of Esophageal Varices. *ArchSurg* [Internet]. 1977;112(11):1317. Available from: <http://dx.doi.org/10.1001/archsurg.1977.01370110051005>
  31. Orozco H, Takahashi T, Mercado MA, Prado E, Chan C. Surgical management of extrahepatic portal hypertension and variceal bleeding. *World J Surg* [Internet]. 1994;18(2):246–50. Available from: <http://dx.doi.org/10.1007/bf00294409>
  32. Selzner M, Tuttle-Newhall JE, Dahm F, Suhocki P, Clavien PA. Current Indication of A Modified Sugiura Procedure in The Management of Variceal Bleeding. *J Am Coll Surg* [Internet]. 2001;193(2):166–73. Available from: [http://dx.doi.org/10.1016/s1072-7515\(01\)00937-1](http://dx.doi.org/10.1016/s1072-7515(01)00937-1)
  33. Irawan H, Mulyawan IM. & Combination of modified Sugiura technique and proximal splenorenal shunt for the management of portal vein thrombosis in noncirrhotic portal hypertension&lt;p&gt; Clin Exp Gastroenterol [Internet]. 2019;Volume 12:149–56. Available from: <http://dx.doi.org/10.2147/ceg.s188200>
  34. Feng AC, Liao CY, Fan HL, Chen TW, Hsieh CB. The modified Sugiura procedure as bridge surgery for liver transplantation: a case report. *J Med Case Rep* [Internet]. 2015;9(1). Available from: <http://dx.doi.org/10.1186/s13256-015-0522-y>



This work is licensed under a Creative Commons Attribution