

Anaesthetic management in the patient with thoracic–lumbar intradural tumor accompanied by heart failure and atrial fibrillation: a case report



Satrio Adi Wicaksono^{1*}, Taufik Eko Nugroho¹, Sulistiyati Bayu Utami²

ABSTRACT

Background: Spinal cystic intradural Schwannoma is a type of tumor that is rarely found, with an incidence of 0.3–0.5/100,000 person per year. The operative procedure for this tumor was simple. However, some patients showed other comorbidities, such as heart failure with low ejection fraction (EF) and atrial fibrillation. Such cases are a challenge to the anaesthesiologist as they are most commonly complicated by progressive cardiac failure.

Case Presentation: A 68-year-old woman was consulted by the Anaesthesiology Department in dr. Kariadi General Hospital Semarang in April 2019. She had been experiencing right lower extremity and lower back pain since April 2018, and they have been getting worse since two weeks ago. She also complained of shortness of breath two weeks before, accompanied by typical symptoms and signs of heart failure. Her electrocardiogram showed atrial fibrillation, and her echocardiogram showed an LVEF of 33.7%. Magnetic resonance imaging (MRI) showed two lobulated intradural–extramedullary cystic lesions at thoracic vertebrae 12 until lumbar vertebrae 1 (VTh12–L1) that were a high suspicion of Schwannoma on the anterior aspect and the lateral aspect accompanied by spinal cord compression at that level. The drugs used for premedication were metoclopramide 10 mg and ranitidine 50 mg, for induction was fentanyl 100 µg, and for maintenance were dobutamine 10 µg/kgBW/minute, rocuronium bromide 30 mg/hour via syringe pump, opioid fentanyl 100 µg and muscle relaxant using rocuronium bromide 40 mg. The patient was hemodynamically stable throughout the surgery, and blood loss was minimal.

Conclusion: In patients with heart problems, a moderate reduction in contractility and heart rate often occurs and may induce mild to severe bradyarrhythmia or tachyarrhythmia related to induction agents. It is important to maintain adequate cardiac output that requires inotropic agents to augment contractility and improve circulation. As an inotropic choice, a β-agonist (e.g., dobutamine) causes less vasodilation, increased contractility, and adjuncts to augment contractility in the setting of significant hypotension.

Keywords: atrial fibrillation, chronic heart failure, ejection fraction, spinal cystic intradural Schwannoma.

Cite This Article: Wicaksono, S.A., Nugroho, T.E., Utami, S.B. 2022. Anaesthetic management in the patient with thoracic–lumbar intradural tumor accompanied by heart failure and atrial fibrillation: a case report. *Bali Medical Journal* 11(3): 1282-1288. DOI: 10.15562/bmj.v11i3.3514

¹Department of Anaesthesiology and Intensive Therapy, Faculty of Medicine, Universitas Diponegoro/ Diponegoro National Hospital, Semarang, Central Java, Indonesia;

²Department of Cardiology and Vascular Medicine, Faculty of Medicine, Universitas Diponegoro/ Diponegoro National Hospital, Semarang, Central Java, Indonesia;

*Corresponding author:

Satrio Adi Wicaksono;
Department of Anaesthesiology and Intensive Therapy, Faculty of Medicine, Universitas Diponegoro/ Diponegoro National Hospital, Semarang, Central Java, Indonesia;

drsaw11@yahoo.com

Received: 2022-07-02

Accepted: 2022-08-14

Published: 2022-09-26

INTRODUCTION

Schwannomas are the most common primary tumors of the nerves. Schwannomas are slow-growing, benign, encapsulated tumors that originate from the Schwann cells in the myelin sheath of nerve fibers. Schwannomas are generally single tumors and account for 26-30% of all intraspinal tumors that involve the lumbar spinal nerves. It can arise as sporadic isolated lesions or associated with neurofibromatosis type II.¹

Schwannomas are generally solid or heterogeneous solid tumors and are rarely cystic. Spinal cystic intradural Schwannoma is rarely found, with an incidence of 0.3–0.5/100,000 person per year. Spinal intradural extramedullary

Schwannoma has a good prognosis if they are diagnosed and removed early.^{2,3}

Most of the spinal Schwannoma, which is about 48% of the spinal Schwannoma, was located in the lumbar region. Schwannoma in the lumbar region can silently occur for a long time because of its slow growth. The clinical symptoms usually present if the tumor size is large and causes pressure on the nerve.²⁻⁵ Benign schwannomas can degenerate into cystic formation, calcification, bleeding and hyalinization.⁴⁻⁶

The spinal tumor will show more complicated clinical symptoms and more comprehensive management when accompanied by cardiac problems, such as heart failure (HF) and atrial fibrillation (AF). HF is a common cardiac

complication of non-cardiac surgery, often emerging in patients with known chronic heart failure, but it may present in asymptomatic patients with diastolic dysfunction or preserved ejection fraction (pEF). The incidence of primary cardiac complications after non-cardiac surgery was between 2% and 3.5%.⁷ The 30-day postoperative mortality was 9.3% in non-ischemic HF patients undergoing non-cardiac surgery, and the hospitalization rate at one month was 15.5%.⁷

HF is a pathological condition in which the heart is unable to pump sufficient blood to the rest of the body because it is either not capable of filling with a sufficient volume of blood or generating sufficient force to pump out enough blood.^{7,8} Ejection fraction (EF, is

a measurement that indicates how well the heart is functioning in diagnosing and tracking heart failure (HF). In HF, myocardial remodeling usually continues and causes the clinical syndrome of HF.⁸⁻¹⁰

Heart failure is classified as HF with reduced ejection fraction (HFrEF), HF with preserved ejection fraction (HFpEF), or HF with mid-range ejection fraction (HFmrEF). HF-pEF shows impaired muscle relaxation and impaired left ventricular filling. The normal range of EF varies from 55 to 70%. Low EF is when EF falls below 55%. If EF is 35% or below, then it is called a very low ejection fraction which is a very high-risk group for developing dangerous cardiac arrhythmia.^{7,8,11}

Diagnostic tests will be more sensitive in HF patients with a low ejection fraction. Diagnostic tests are often less sensitive to HF patients with a normal ejection fraction. Echocardiography is a useful method for evaluating systolic and diastolic dysfunction.¹²

Special approaches need to be taken in perioperative management in patients with HF and AF.^{7,9,13} In patients with heart problems, a moderate reduction in contractility and/or heart rate often occurs and may induce mild to severe bradyarrhythmia or tachyarrhythmia related to induction agents. Anaesthetic Management is aimed at maintaining adequate cardiac output that sometimes requires inotropic agents to augment contractility and improve circulation. A β -agonist (e.g., dobutamine) as an inotropic choice causes less vasodilation, increased contractility, and adjuncts to augment contractility in the setting of significant hypotension.^{7,9,13} This case report is aimed to report our experience in successfully managing a patient with thoracic-lumbar intradural tumor accompanied by heart failure and atrial fibrillation.

CASE PRESENTATION

A 68-year-old woman had been experiencing right lower extremity and lower back pain since April 2018, which led them to seek help from local medical clinics. The patient's symptoms were occasionally alleviated by medication and physiotherapy.

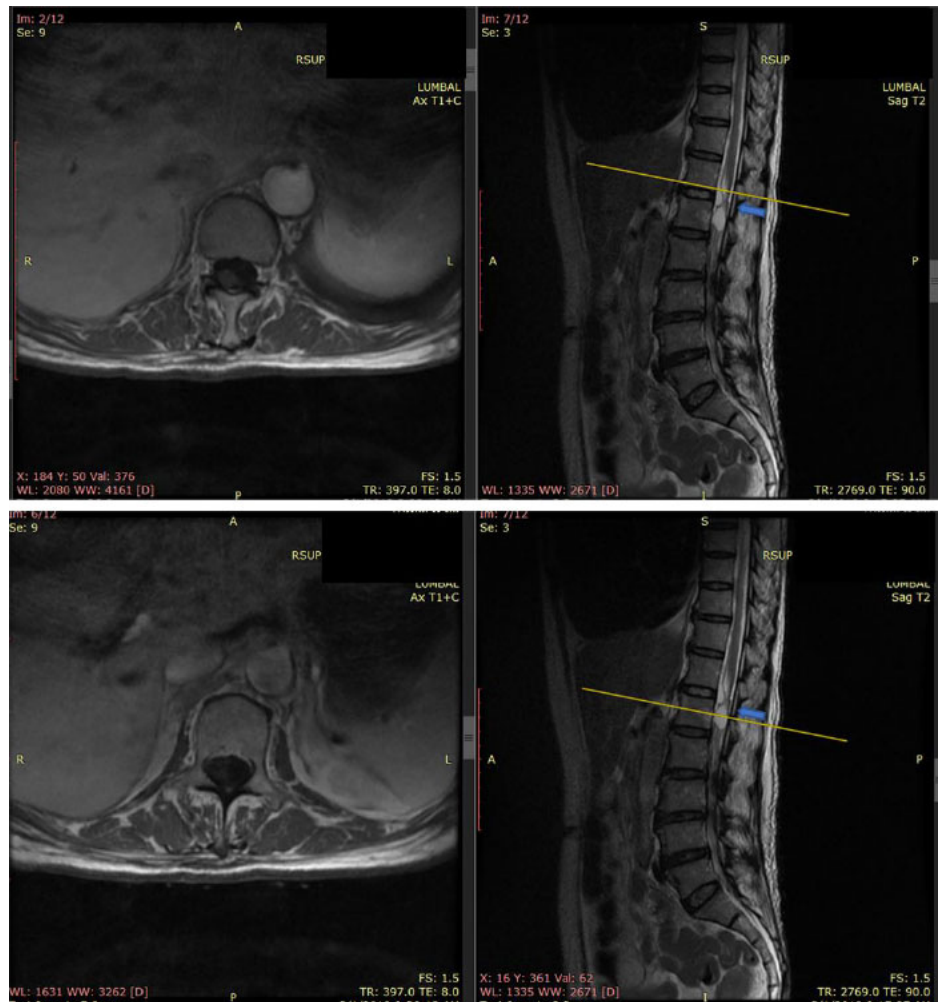


Figure 1. Magnetic Resonance Imaging (MRI) of patient with Schwannoma (blue arrow)

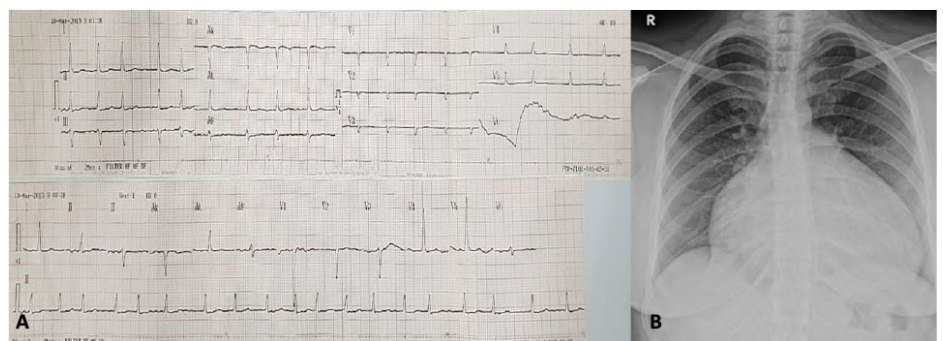


Figure 2. A) Electrocardiogram, and; B) Chest X-ray of the patient before surgery.

The patient complained of pain in both her feet, and it had been getting worse two weeks previously. She was directed for magnetic resonance imaging (MRI) examination, which found two lobulated intradural-extramedullary cystic lesions at the level of thoracic vertebrae 12 to lumbar vertebrae 1 (VTh12–L1) on the anterior aspect and the lateral aspect accompanied

by spinal cord compression at that level. There was no lumbar disc herniation. This intradural tumor was a high suspicion of Schwannoma. An intradural structure, which following gadolinium injection became increasingly distinct, was noted and diagnosed as a schwannoma (Figure 1).

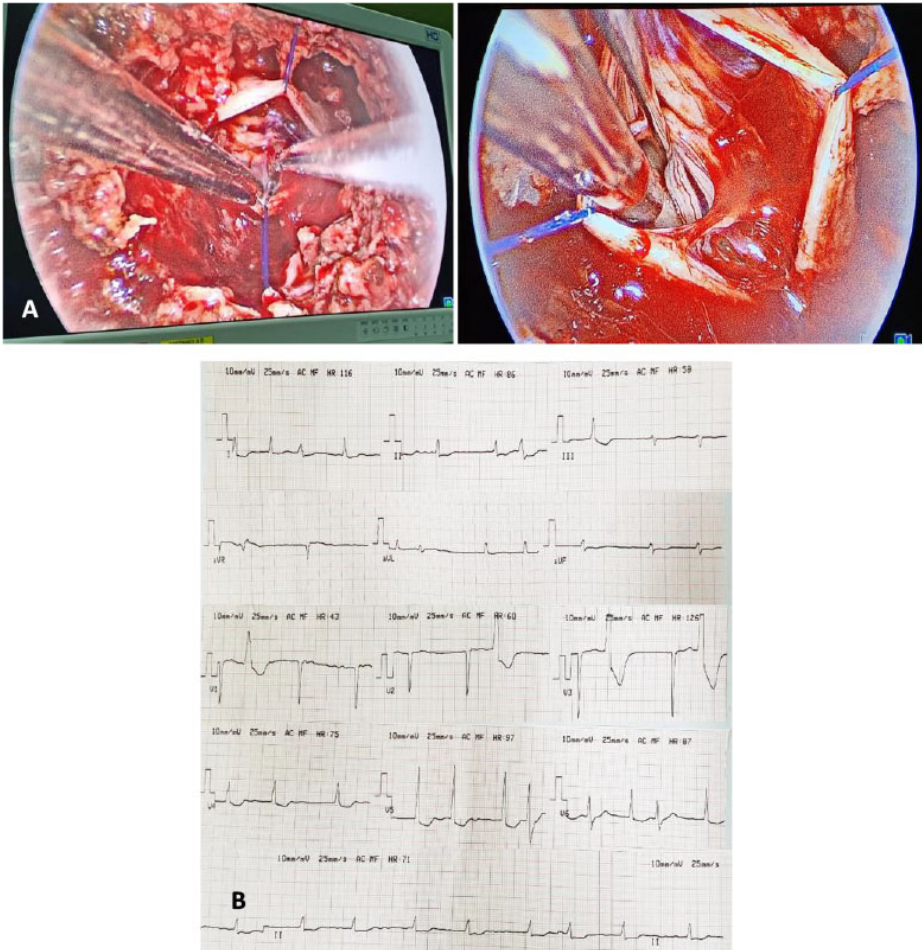


Figure 3. A) Appearance during the surgical approach, and; B) perioperative electrocardiogram.

The patient was then planned for elective surgery and consulted by the Department of Anaesthesiology and Intensive Therapy at dr. Kariadi General Hospital Semarang before surgery in April 2019. In the outpatient clinic, she also complained of shortness of breath two weeks before. She also showed typical symptoms and signs of heart failure. Her regular medications administered before surgery were angiotensin-converting enzyme inhibitors, ramipril 5 mg once daily; a mineralocorticoid-receptor-antagonists, spironolactone 25 mg once daily; beta blocker bisoprolol 2.5 mg once daily; and furosemide 20 mg once daily.

During a consultation with the Department of Anaesthesiology and Intensive Therapy, she was in a fully awake condition, with a blood pressure of 150/80 mmHg, heart rate of 76 times per minute, a breathing rate of 16 times per minute and peripheral oxygen saturation of 98%.

Her thoracic examination revealed fine crackles on the basal of both lungs and edema in both lower extremities. Her right lower leg was amputated 4 months ago due to blockage of the arteries in the right lower extremity. Neurological examination showed normal motoric in bilateral inferior extremities (5/5/5/5). However, there was a sensory disorder in the form of hypesthesia in bilateral inferior extremities at the level radix spinal lumbar. The bladder and bowel function was normal, and no reduction in deep tendon reflex was identified. Neurological examination revealed no weakness of the extensor hallucis longus and the gluteus medius. The results of the straight leg-raising test and Patrick's test were normal.

Laboratory examination obtained haemoglobin of 16.0 g/dL, haematocrit 39.8 %/ erythrocyte 4,480,000 / μ L, platelet count of 443,000 / μ L, random blood

glucose of 105 mg/dL, urea 19 mg/dL, creatinine 0.57 U/L, electrolytes (sodium 139 mmol/L, potassium 3.3 mmol/L, chloride 97 mmol/L, calcium 2.40 mmol/L and magnesium 0.79 mg/dL). Her electrocardiography (ECG) showed atrial fibrillation (AF) (Figure 2A).

Thorax X-ray examination showed pancardiomegaly, aortic arch elongation and early pulmonary edema with minimal pericardial effusion and left pleural effusion (Figure 2B). Echocardiography showed dilatation in all cardiac chambers, minimal pericardial effusion, left pleural effusion, decreased global systolic and segmental left ventricular (LV) function with left ventricular ejection fraction (LVEF) of 33.7%, mild mitral regurgitation (MR), mild aortic regurgitation (AR), mild tricuspid regurgitation (TR) and mild pulmonary regurgitation (PR), and low probability for pulmonary hypertension (PH).

When the patient arrived in the operating room, the general condition was fully awake with a blood pressure of 140/73 mmHg, heart rate of 94 times/minute, irregularly irregular, respiratory rate of 14 times/minute, and peripheral oxygen saturation of 98%.

To remove the mass, the patient underwent a total Th12-L1 laminectomy. The intradural tumor was successfully removed. The dura-mater of the Th12-L1 was opened but still allowed the nerve fibers involved in the tumor to be identified. The involved fibers surrounding the tumor were cut, and the lesion was resected, preserving the intact nerve fibers (Figure 3A).

Macroscopically, the tumor was an ovoid mass measuring 8.0 \times 5.0 \times 5.0 cm, with a fresh weight of 110 g. The outer surface was grey-tan and smooth with a lobulated appearance. The cut surface was multi-loculated with areas of firm tissue, pale tan, and sanguineous fluid (Figure 3A).

The operation took approximately 5 hours. The patient's hemodynamic condition during the operation was stable, with the general condition being: blood pressure ranging from 130 to 160 / 70 to 90 mmHg, heart rate of 60–70 times per minute, and peripheral oxygen saturation of 100% (Table 1). ECG monitor during

Table 1. Intraoperative hemodynamic data.

Minute to	MAP (mmHg)	HR (bpm)	T (Celsius)	RR (breath per minute)	SpO2 (%)
15"	103	76	36.2	16	98
30"	103	74	35.8	18	98
45"	100	78	35.2	16	98
60"	90	76	35.4	14	98
75"	100	74	36,7	14	98
90"	87	72	36,5	14	98
105"	90	76	36.5	16	98
120"	87	78	36.7	16	98
135"	76	74	37.0	16	98
150"	93	96	36.5	14	98
165"	76	76	36.7	14	98

*Abbreviation: MAP (Mean Arterial Pressure), HR (Heart Rate), T (Temperature), RR (Respiration Rate), SpO2 (Oxygen Saturation)

Table 2. Post-operative hemodynamic data.

Time	MAP (mmHg)	HR (bpm)	T (Celsius)	RR (breath per minute)	SpO ₂ (%)
17.00	103	112	37.3	12	100
17.30	100	121	37.9	12	100
18.00	90	152	38.4	12	99
18.30	87	139	38.8	14	99
19.00	93	154	39.1	14	98
19.30	76	211	39.6	14	98
20.00	93	226	39.4	14	98
20.30	76	204	39.2	14	98
21.00	93	180	38.8	14	99
22.00	100	166	39	14	100
23.00	103	171	37.8	14	100
00.00	93	104	37.4	14	100

*Abbreviation: MAP (Mean Arterial Pressure), HR (Heart Rate), T (Temperature), RR (Respiration Rate), SpO2 (Oxygen Saturation)

surgery occasionally showed atrial fibrillation with ventricular premature contractions (PVCs) (Figure 3B).

The drugs used for premedication were metoclopramide 10 mg and ranitidine 50 mg, for induction was fentanyl 100 µg, and for maintenance was using Dobutamine 10 µg/kgBW/minute via syringe pump, and rocuronium bromide 30 mg/hour via syringe pump, opioid using Fentanyl 100 µg and muscle relaxant using rocuronium bromide 40 mg.

After the surgery was finished, the patient was transferred to the recovery room with a blood pressure of 160/80 mmHg, heart rate of 80 times/minute, respiratory rate of 18 times/minute, and peripheral oxygen saturation of 99% (Table 2). The neurological status improved by the sixth week postoperatively. At the eighth month postoperatively, the patient's symptoms improved significantly, with only a residual abnormal sensation on the

skin of the right calf, which did not affect the patient's normal active lifestyle.

DISCUSSION

Our case report described a patient with intradural Schwannoma in the level of VTh12-L1 accompanied by HF and AF whose early symptoms initially improved with conservative treatment, but later symptoms gradually worsened until there was a neurological deficit. Further investigation using contrast-enhanced MRI revealed an intradural extramedullary tumor. Meanwhile, the patient also had decreased global and segmental LV systolic function with an LVEF of 33.7%.

Lower back pain generally results from larger tumors, which impinge on multiple spinal root levels.¹⁴ Tumours in the cauda equina often reach a considerable size without painful symptoms due to the mobility of the roots and the

wide intradural space.¹⁵ However, the neurological impairment of the patient presented in our case resulted from intradural compression in VTh12-L1 and not in cauda equina. Similar to our case, most intradural tumors are a slowly progressive, indolent course and, thus, there may be an interval period of several months prior to the symptoms becoming evident. However, it can be locally aggressive and cause neurological compromise.^{1,5}

The coexistence of an HF and AF in a patient with an intradural spinal tumor has not been discussed before. The spinal tumor will show more complicated clinical symptoms and more comprehensive management when accompanied by cardiac problems, such as HF and AF. In our case, it was getting more complicated since the patient was experiencing peripheral arterial disease (PAD) both in terms of diagnosis and management.

The diagnosis of the intradural spinal tumor was obscured by PAD since both intradural spinal tumors and PAD might show similar symptoms of leg pain. However, we are not certain whether the PAD was directly causally correlated to the intradural tumor or not.

Differ from our case report, Hwang SK et al., Almobarak AA et al., and Koujanian S et al. have reported a case of primary Schwannoma of the heart or pericardial Schwannoma adjacent to the left atrium with a chief complaint of resting sharp chest pain and benign dyspnea.¹⁶⁻¹⁸ While D'Amato et al. reported a malignant Schwannoma or neurofibrosarcoma of the pericardium with a symptom of acute heart failure. There was a postoperative complication during the intensive care unit stay with orthopnoea and signs of hypoperfusion in the malignant Schwannoma case.¹⁹ The last case may be mimicking our present case, in which, in our case, the orthopnoea and all heart failure symptoms were primarily caused by heart failure, but the case reported by D'Amato et al. was caused by extrinsic compression of the tumor.¹⁹

Heart failure (HF) with EF under 40% indicates HF with reduced left ventricular ejection fraction (HFrEF), which is referred to as systolic heart failure. It is when the heart muscle is unable to pump effectively to deliver sufficient oxygen-rich blood into the target organ. Patients with HFrEF have elevated left ventricular end-diastolic pressure (LVEDP), left atrial pressure (LAP), and central venous pressure (CVP) due to impaired relaxation and contraction in the enlarged and noncompliant ventricles.^{7,11}

Preoperatively, our patient had elevated LVEDP and LAP that might imply an increased transpulmonary venous and capillary pressure gradient (TPG) and low absorptive capabilities of alveolar capillaries, which led to mild pulmonary congestion. The elevated TPG and higher right ventricle (RV) afterload resulted in an elevated CVP and raised hepatic venous pressure (HVP), leading to liver congestion.⁷ Patients with very low EF <35%, as in our case report, could be at high risk for anesthesia as life-threatening arrhythmia and symptomatic heart failure were possible to occur.⁹ Any life-

threatening arrhythmia that might occur in this patient needs preventive treatments and prompt treatments; otherwise, it might lead to sudden cardiac arrest or sudden death.^{7,9}

Heart failure with preserved ejection fraction (HFpEF), which is known as diastolic heart failure, is when the left ventricle loses its ability to relax normally because the cardiac muscle has become stiff. The heart can't properly fill with blood during the resting period between each beat. In diastolic heart failure, heart muscle contracts normally, but the ventricles do not relax as they should during ventricular filling.^{7,9}

Impaired diastolic function was an important finding that also occurred in our case. Normal sinus rhythm was required to gain optimal diastolic filling. However, our patient showed atrial fibrillation instead of sinus rhythm. Patients with atrial fibrillation would lose the atrial systole (atrial kick) that was required for diastolic filling of the ventricles, which it was bringing over for up to 75% of end-diastolic volume. Furthermore, tachyarrhythmia may reduce the diastolic filling time of both the ventricles and the coronaries and may also be life-threatening. Therefore, in general, medication, i.e., vasodilators that do not induce tachycardia, is preferable.^{9,10} Amiodarone is the available drug to treat these arrhythmias as it has the least myocardial depressant effect.

The cardiovascular system during the perioperative period should be monitored, especially when administering anesthesia in patients with major surgery and pre-existing cardiac disease, as in our case. Anaesthesia administration may lead to an increased cardiac output which can be easily achieved by normal patients but may result in substantial morbidity and mortality in those with cardiac disease. Post-operative events sometimes cause death, including arrhythmias and multiple organ failures secondary to low cardiac output.¹³

The perioperative care of patients with depressed EF involves balancing the need for perfusion and the heart's ability to perfuse the rest of the body while maintaining its own blood flow. Patients with very low EF require preoperative evaluation, including identification of

risk factors and appropriate anesthetic techniques and drugs, as well as optimization of medical therapy and monitoring. The anesthetic management in our patients with major surgery and low EF included optimization of preload and forward flow, maintenance of stable hemodynamics, and prevention of complications such as arrhythmias and precipitation of decompensated heart failure.^{9,10,13} Maintenance of forwarding flow was directed to reduce coronary ischemia, pulmonary hypertension and acute or chronic end-organ dysfunction due to hypoperfusion, to promote inotropy without inducing or worsening ischemia, and to establish the patient's condition post-operatively.⁸

The anesthesia management included the avoidance of drug-induced myocardial depression and arrhythmias, as well as the control of peripheral vasodilatation and venous return to maintain adequate cardiac output, organ flow and perfusion pressure. Any changes in either of these variables should be minimized.^{9,10} It was needed to improve oxygenation and heart-lung interaction by reducing alveolar-interstitial edema and TPG and keeping a normal low CVP and HVP.¹⁰

Mechanical ventilation, such as intermittent positive-pressure ventilation (IPPV), may increase intrathoracic pressure, reduce venous return and cardiac output, and lead to circulatory arrest, so we need to maintain the optimal intrathoracic pressure. Large tidal volumes can reduce cardiac filling; thus, a tidal volume of 6-8 ml/kgBW can be used.^{11,20}

Drugs to treat pre-existing heart failure, arrhythmias, hypertension, or ischemic heart diseases should be continued during the perioperative period as long as they are well tolerated.²⁰ The mainstays of chronic medical management for patients with low EF included the use of angiotensin-converting enzyme inhibitors or angiotensin II receptor blockers to slow cardiac remodeling, beta-adrenergic antagonists, diuretics, and salt restriction to minimize fluid retention. Aldosterone antagonists were also used in this patients with severe symptoms of heart failure with concomitant monitoring for renal dysfunction and serum potassium.^{7,20} Other reports showed that afterload

reducing agents, including calcium channel blockers (CCBs) and phosphodiesterase-3 (PD-3) inhibitors, were used to decrease systemic vascular resistance and promote forward flow, but not in heart failure.^{7,12}

Induction of general anesthesia sometimes leads to vasodilation, loss of sympathetic tone and a shift of volume from the intrathoracic to the extrathoracic compartment. Blood pressure is often decreased after induction and during maintenance of anesthesia. Induction reduces systemic arterial pressure by 20%-30%, while intubation increases blood pressure by 20-30 mmHg, and drugs such as nitrous oxide can reduce cardiac output by up to 15%. Mechanical ventilation influences normal heart-lung interaction.^{10,13,20}

In our case, we used fentanyl 100 µg for induction instead of propofol. Among induction agents, propofol has the most obvious effects on systemic vascular resistance. In patients with ischemic heart disease and good ventricular function who had surgery, Vermeyen et al. showed that there was a negative inotropic effect of propofol-fentanyl based on a decrease in the left ventricular stroke index with unchanged filling pressure.²¹ Furthermore, there was a myocardial depressant effect on propofol in patients with impaired left ventricular function. Here propofol might interfere with myocardial contractility and relaxation, and the severity was related to the concentration of propofol in the blood.^{10,13,21}

Some reviews showed that there were more hemodynamic changes in propofol in comparison to fentanyl in patients with low EF. Patients with propofol showed a moderate reduction in heart rates compared to patients with fentanyl in patients with heart problems. Severe bradycardia related to propofol could happen when combined with fentanyl. Compared with other intravenous anesthetics, the induction dose of propofol seems to show blood pressure reduction, higher incidence of respiratory depression, and short-lived apnoea. Possible mechanisms for the hypotension may relate to (1) its action on peripheral vasculature (vasodilatation), (2) decreased myocardial contractility, (3) resetting of the baroreflex activity and (4) inhibition

of the sympathetic nervous system outflow. However, other studies have shown that cardiac output is not different when comparing propofol, etomidate or midazolam as induction agent.^{20,22}

Inhalational anesthetics reduce myocardial contractility in a dose-dependent manner, but effects differ between the different agents. In our case, the anesthetic agent used was sevoflurane 1 MAC (2%) as volatile anesthetic agents that offer better cardio-protection than intravenous agents.¹³ Volatile anesthetic agents such as sevoflurane, unlike isoflurane and desflurane, does not induce a tachycardia. Sevoflurane and isoflurane have cardioprotective effects similar to those induced by ischaemic preconditioning. While isoflurane is a common anesthetic for patients undergoing coronary revascularization and seems to have cardioprotective properties.^{11,13}

Patients with impaired LV function mostly rely on their preload to maintain ventricular filling and also on increased sympathetic tone to maintain cardiac output and tissue perfusion. Perioperatively, they are highly sensitive to negative inotropic agents and abnormal filling pressure, so these patients often require close monitoring and an early administration of the inotropic agents, such as dobutamine, instead of using additional fluids to maintain cardiac output to avoid hemodynamic alterations, vascular overload and pulmonary oedema.¹³

Inotropes were needed to augment contractility and to increase forward flow and perfusion. The inotropic choice is a β-agonist (e.g., dobutamine) or a phosphodiesterase-3 inhibitor (e.g., milrinone). Their characteristics in increasing contractility may offset their effect on reducing systemic vascular resistance (SVR), especially milrinone. As in our case, we choose to use dobutamine as an inotropic to control perioperative hemodynamic alterations. Dobutamine, starting at 2.5 – 5.0 µg/kgBW/min, causes lesser vasodilation. Although inotropic support might increase myocardial oxygen demand and might decrease oxygen supply by increasing ventricular wall tension, some reports showed that dobutamine

was not associated with increased mortality in patients with heart failure compared with controls.^{11,20} Meanwhile, the inotropic properties and dose-dependent vasopressor effect from the α1 agonists, dopamine, norepinephrine, and epinephrine are useful adjuncts to augment contractility in the setting of significant hypotension.^{10,13}

CONCLUSION

There was a challenge in the management of anesthesia in patients with impaired ventricular function with low ejection fraction. Special consideration should be taken in administering propofol or fentanyl due to myocardial depressant effect or negative inotropic effect. Furthermore, it is important to maintain the hemodynamic stability and the adequacy of cardiac output that may require an inotropic agent to augment contractility and improves circulation, such as β-agonist dobutamine. It becomes a strategy of anesthesia to maintain forward flow; reduce coronary ischemia, pulmonary hypertension and acute or chronic end-organ dysfunction due to hypoperfusion; promote inotropy without inducing or worsening ischemia and maintain the patient's post-operative condition.

CONFLICT OF INTEREST

The authors affirm no conflict of interest in this study.

FUNDING

This study was all funded by the author.

AUTHOR CONTRIBUTION

All authors contributed to this research, starting from planning to the preparation of the manuscript publication.

REFERENCES

1. Van Goethem JW, van den Hauwe L, Ozsarlak O, De Schepper AM, Parizel PM. Spinal tumors. *Eur J Radiol.* 2004;50(2):159-176. doi:10.1016/j.ejrad.2003.10.021.
2. Baek SW, Kim C, Chang H. Intradural schwannoma complicated by lumbar disc herniation at the same level: A case report and review of the literature. *Oncol Lett.* 2014;8(2):936-938. doi:10.3892/ol.2014.2181.
3. Pan J, Wang Y, Huang Y. Coexistence of intervertebral disc herniation with intradural

- schwannoma in a lumbar segment: a case report. *World J Surg Oncol.* 2016;14:113. Published 2016 Apr 18. doi:10.1186/s12957-016-0864-y.
4. Arnautovic K, Arnautovic A. Extramedullary intradural spinal tumors: a review of modern diagnostic and treatment options and a report of a series. *Bosn J Basic Med Sci.* 2009;9 Suppl 1:40-45. doi:10.17305/bjbm.2009.2755.
 5. Lenzi J, Anichini G, Landi A, et al. Spinal Nerves Schwannomas: Experience on 367 Cases-Historic Overview on How Clinical, Radiological, and Surgical Practices Have Changed over a Course of 60 Years. *Neurol Res Int.* 2017;2017:3568359. doi:10.1155/2017/3568359.
 6. Bhargah A, Jayantika IGABK, Prabawa IPY, and Manuaba IBP. Spontaneous conversion to sinus rhythm in atrial fibrillation after dual antiplatelet and anticoagulant therapy in patients with unstable angina. *Bali Medical Journal.* 2020;9(3). p664-667. <https://doi.org/10.15562/bmj.v%vi%i.2011>.
 7. Ponikowski P, Voors AA, Anker SD, et al. 2016 ESC Guidelines for the diagnosis and treatment of acute and chronic heart failure: The Task Force for the diagnosis and treatment of acute and chronic heart failure of the European Society of Cardiology (ESC) Developed with the special contribution of the Heart Failure Association (HFA) of the ESC [published correction appears in *Eur Heart J.* 2016 Dec 30;]. *Eur Heart J.* 2016;37(27):2129-2200. doi:10.1093/eurheartj/ehw128.
 8. Chua JH, Nguyen R. Anesthetic management of the patient with low ejection fraction. *Am J Ther.* 2015;22(1):73-79. doi:10.1097/MJT.0b013e31826fc458.
 9. Shaheen MSA, Sardar K, Chowdhury AKMN, Rahman MM, Alam MNA, Ahmed R, et al. Ejection Fraction <35% - Anaesthetic Experience of 236 Cases: A Retrospective Study. *Anwer Khan Modern Med Coll J.* 2018;9(2):114-20. DOI: <https://doi.org/10.3329/akmmcj.v9i2.39206>.
 10. Mittal AK, Chowdhury I, Arora M, Jain CR. Anesthetic management of a patient with heart failure and reduced ejection fraction for radical cholecystectomy with liver resection surgery. *Indian Anaesth Forum.* 2017;18(1):19-22. DOI:10.4103/TheIAForum.TheIAForum_5_17.
 11. Magner JJ, Royston D. Heart failure. *Br J Anaesth.* 2004;93(1):74-85. <https://doi.org/10.1093/bja/ael167>.
 12. Larsen JR, Torp P, Norrild K, Sloth E. Propofol reduces tissue-Doppler markers of left ventricle function: a transthoracic echocardiographic study. *Br J Anaesth.* 2007;98(2):183-188. doi:10.1093/bja/ael345.
 13. Ryu T, Song SY. Perioperative management of left ventricular diastolic dysfunction and heart failure: an anesthesiologist's perspective. *Korean J Anesthesiol.* 2017;70(1):3-12. doi:10.4097/kjae.2017.70.1.3.
 14. Caputo LA, Cusimano MD. Schwannoma of the cauda equina. *J Manipulative Physiol Ther.* 1997;20(2):124-129.
 15. Kagaya H, Abe E, Sato K, Shimada Y, Kimura A. Giant cauda equina schwannoma. A case report. *Spine (Phila Pa 1976).* 2000;25(2):268-272. doi:10.1097/00007632-200001150-00021.
 16. Hwang SK, Jung SH. Schwannoma of the heart. *Korean J Thorac Cardiovasc Surg.* 2014;47(2):141-144. doi:10.5090/kjtcs.2014.47.2.141.
 17. Almobarak AA, AlShammari A, Alhomoudi RI, et al. Benign Pericardial Schwannoma: Case Report and Summary of Previously Reported Cases. *Am J Case Rep.* 2018;19:90-94. Published 2018 Jan 24. doi:10.12659/ajcr.907408.
 18. Koujanian S, Pawlowicz B, Landry D, Alexopoulou I, Nair V. Benign cardiac schwannoma: A case report. *Human Pathology: Case Reports.* 2017;8:24-6. <https://doi.org/10.1016/j.ehpc.2017.01.003>.
 19. D'Amato N, Correale M, Irevia R, Di Biase M. A rare cause of acute heart failure: malignant schwannoma of the pericardium. *Congest Heart Fail.* 2010;16(2):82-84. doi:10.1111/j.1751-7133.2009.00124.x.
 20. Fleisher LA, Fleischmann KE, Auerbach AD, et al. 2014 ACC/AHA guideline on perioperative cardiovascular evaluation and management of patients undergoing noncardiac surgery: a report of the American College of Cardiology/American Heart Association Task Force on practice guidelines. *J Am Coll Cardiol.* 2014;64(22):e77-e137. doi:10.1016/j.jacc.2014.07.944.
 21. Vermeyen KM, Erpels FA, Janssen LA, Beeckman CP, Hanegreefs GH. Propofol-fentanyl anaesthesia for coronary bypass surgery in patients with good left ventricular function. *Br J Anaesth.* 1987;59(9):1115-1120. doi:10.1093/bja/59.9.1115.
 22. Searle NR, Sahab P. Propofol in patients with cardiac disease. *Can J Anaesth.* 1993;40(8):730-747. doi:10.1007/BF03009770.



This work is licensed under a Creative Commons Attribution