

Diagnostic challenges in Waldenström macroglobulinemia: a case report



Stella Pravita¹, Ugroseno Yudho Bintoro^{2*}, Putu Niken Ayu Amrita²

ABSTRACT

Background: Waldenstrom macroglobulinemia (WM) is a rare, dormant hematologic disease. It often manifests in people over 60 years of age and considered a hereditary disorder with MYD88 and CXCR4 genes mutation. In Indonesia, WM medical records is limited, causing potential misdiagnose or mistreatment. This article reported a case of WM patient and its challenging diagnosis establishment.

Case Presentation: A 67-year-old woman was referred with chief complaints of extremities swelling with recurrent anemia, bone pain, and elevated renal function. Protein electrophoresis indicated monoclonal gammopathy, suspected as multiple myeloma. However, further examinations did not support the diagnosis of multiple myeloma as the results revealed increased B2 microglobulin (5.65mg/L). IgM immunofixation suggested IgM lambda monoclonal gammopathy. Bone marrow aspiration (BMA) showed dominant lymphoplasmacytic cells (68%) and flowcytometry test of serum plasma indicated positive CD10 and CD34, whereas CD5 and CD19 were negative. The differential diagnoses have also been ruled out one by one to provide appropriate treatment for the patient. After all examinations, the patient was finally diagnosed with WM and treated with bortezomib, low-dose dexamethasone, and rituximab (BDR) regimen for five cycles.

Conclusion: WM is rare case of hematologic disease and the diagnosis of the case could face challenges due to diagnostic difficulty. Protein electrophoresis and BMA could help to improve the diagnosis process.

Keywords: Waldenstrom macroglobulinemia, WA, diagnosis, challenges, myeloma.

Cite This Article: Pravita, S., Bintoro, U.Y., Amrita, P.N.A. 2022. Diagnostic challenges in Waldenström macroglobulinemia: a case report. *Bali Medical Journal* 11(1): 202-204. DOI: 10.15562/bmj.v11i1.3160

¹Specialist Program of Internal Medicine, Faculty of medicine, Universitas Airlangga/Dr. Soetomo Hospital, Surabaya, Indonesia;

²Department of Internal Medicine, Universitas Airlangga/Dr. Soetomo Hospital, Surabaya, Indonesia;

*Corresponding author:
Ugroseno Yudho Bintoro;
Department of Internal Medicine,
Universitas Airlangga/Dr. Soetomo
Hospital, Surabaya, Indonesia;
ugroseno@fk.unair.ac.id

Received: 2022-01-25
Accepted: 2022-03-29
Published: 2022-04-08

INTRODUCTION

Waldenström macroglobulinemia (WM) is a rare hematologic disorder with subclinical manifestation. The approximate incidence of the disease is 1-3% of all hematology oncology worldwide. About 1500 new cases have been reported each year with higher prevalence among Caucasians compared to African-Americans.¹ This disease is incurable, slow-growing, late onset, and appears mostly in the elderly.^{2,3}

In Indonesia, however, WM is rarely encountered. A potential explanation for this is might be due to its minimum records in Indonesia. Its resemblance to other diseases such as multiple myeloma makes the disease diagnosis challenging, and the therapy given is might possibly not in accordance with existing guidelines. In addition, insufficient globally accepted diagnostic criteria has hampered the progress in WM disease. Therefore, this case report aimed to provide insight on possible diagnosis that can done and

established towards the patient.

CASE PRESENTATION

A 67-year-old female with chief complaints of swelling in the left leg and right hand for one week admitted at Dr. Soetomo Hospital, Surabaya. The patient experienced numbness, stiffness, shortness of breath, back pain, and fatigue for the past 6 months. No lymphadenopathy or organ enlargement were observed in the patient. The patient had the history of diabetes mellitus controlled by metformin and gliclazid without insulin, as well as possessed the family history of myeloma. No history of hypertension, CVA, or trauma before. Five months ago, the patient was also hospitalized and suspected with multiple myeloma (MM) due to anemia, bone pain, elevated renal function, and monoclonal gammopathy obtained from protein electrophoresis. However, after the treatment, renal function became normal and no bone lytic was found.

Hypercalcemia manifestation did not

meet the criteria of MM. The diagnostic then continued to bone marrow aspiration, indicating the occurrence of dominant lymphoplasmacytic cells (68%) and plasma cell activity, leading to the suspicion of Waldenström macroglobulinemia (Figure 1). Further test was performed and increased B2 microglobulin (5.65 mg/L) was observed. Immunoserology examination showed free light chain Kappa of 18.08 mg/dL and free light chain lambda of 21.38 mg/dL, with kappa/lambda ratio of 0.8457. The IgM Immunofixation assay revealed IgM lambda monoclonal gammopathy. Flowcytometry analysis of plasma serum showed positive CD10 and CD34, whereas CD5 and CD19 were negative. Doppler ultrasound exhibited thrombus in bilateral femoral vein. Based on all the tests results, the patient was diagnosed with Waldenström macroglobulinemia. The patient then underwent a 5-cycles bortezomib, low-dose dexamethasone, and rituximab (BDR) regimen.

DISCUSSION

We reported a case of Waldenström macroglobulinemia (WM) in a 67-year-old female patient. The patient was initially hospitalized due to shortness of breath, complaints of weakness, lack of energy, and shortness of breath during strenuous activities. No complaints of blurred vision, skin abnormalities such as itching and bruising, enlargement of organs or lymph nodes were observed. Bing-Neel syndrome manifestation was also not found; however, there was swelling on one side of the upper and lower extremities as the thrombus was observed through Doppler ultrasound.

WM is rare case of hematologic disease and its diagnosis is considered challenging due to diagnostic difficulty. The main diagnoses of WM include clinical criteria, serum protein test, and bone marrow biopsy. Several other investigations to support WM diagnosis are IgM monoclonal gammopathy examination, bone marrow infiltration with small lymphocytes,⁴ immunofixation, urine electrophoresis protein (40-80% Bence Jones proteinuria), serum β 2-microglobulin test, cytogenetic studies (optional), and the abdomen and pelvis computer tomography (CT).⁵ In this case, the diagnosis was established based on the patient history taking, protein electrophoresis, and flowcytometry tests.

The family history revealed that the patient had a cousin diagnosed with myeloma. Having the first-degree relatives suffering from WM or B cell disorder has been reportedly increased the risk of developing WM in individuals.³ The results of complete blood count showed a reduction in the red blood cells and kidney function. The patient was not tested for immunohistochemistry since bone marrow biopsy was not carried out. As an alternative, the patient was examined for flowcytometry and the results showed positive CD10 and CD34, and negative CD 5 and CD 19. Some other cases showed positive CD10.^{2,6,7} In this case, some discrepancies were observed in the patient's immunophenotype since the sample used for the test was blood serum, in which, the expressed cells might not be obtained optimally compared to bone marrow samples.

The differential diagnoses had also been ruled out to ensure the accuracy

of diagnosis and treatment since WM tends to resemble other disease such as multiple myeloma. The difference of WM and multiple myeloma (MM) is determined by a clinical sign. A patient is categorized as IgM-MM once the patient with MM exhibited an increase IgM levels. In myeloma, plasma cell morphology and bone lytic lesions are found. WM expresses CD19, CD20, and CD22, while IgM-MM expresses CD38 and CD138 which are negative in WM. Clinically, chronic lymphocytic leukemia (CLL) B cells can resemble WM; however, in CLL, lymphadenopathy is generally found. Morphology (small and mature lymphocytes without nucleoli) and immunophenotype (positive CD5 and CD23, which are negative in WM) are considered sufficient for CLL diagnosis.⁸ Asymptomatic patients with IgM monoclonal protein and acquired lymphoplasmacytic infiltration of less than 10% were classified as (IgM-secreting MGUS).^{2,9}

In this case, the patient showed decrease red blood cells which did not meet the criteria for smoldering macroglobulinemia. Furthermore, there was neither increase of white blood cells nor enlargement of lymph nodes during physical examination, suggesting that the patient's diagnosis did not meet B cell CLL criteria. The results of physical and other additional examinations, including bone survey, showed no lytic lesions on the bone as well as no plasma cells in the bone marrow, ruling out the diagnosis of MM or IgM-MM.

There are no definite guidelines for when to start WM therapy, but an increase

in B2M of more than 60g/L with a risk of hyperviscosity symptoms is suggested to initiate therapy. Common indications to start therapy are anemia, Bing Neel syndrome, or organomegaly. In this case report, the patient had clinical symptoms of recurrent anemia upon blood transfusions, indicating that the patient should undergo WM therapy.

Plasmapheresis can be carried out to reduce complaints of hyperviscosity. The combination of anti-CD20 agent (rituximab) remains preferred as the first-line therapy. However, the DRC (Dexamethasone Rituximab Cyclophosphamide) regimen for 6 cycles has a greater response compared to rituximab alone. Bortezomib alone or in combination with rituximab (VR) is very useful for WM and is recommended to be administered subcutaneously at 1-week intervals (1.6 mg / m²). Long-term BDR monitored for 5 cycles demonstrated an

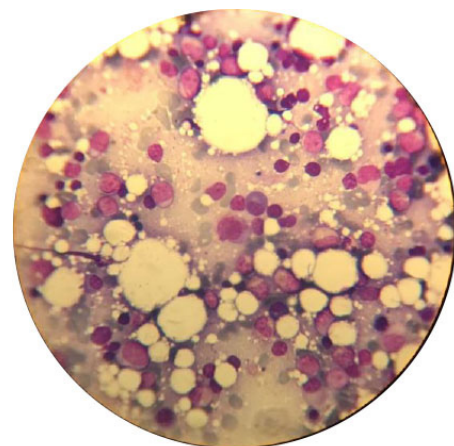


Figure 1. Bone marrow aspiration with lymphoplasmacytic infiltrate (1000x).

Table 1. International prognostic scoring system for WM.

Criteria	Value	The presented case
Factor associated with prognosis		
Age, year	>65	√
Hemoglobin, g/dL	≤ 11.5	√
Platelet Count, no./mL	≤ 100.000	
B2-Microglobulin, mg/L	>3	√
Monoclonal Ig-M, g/dL	>7	
Risk stratum		
Low	0 or 1 (except age)	
Intermediate	2 OR age > 65y	
High	>2	√

Abbreviation: IgM, immunoglobulin M. Adapted from Morel et al.¹³ One point is assigned for each positive factor and the risk score is the sum of points.

acceleration-free disease rate (PFS) of up to 3.5 years with a median response of 5.5 years and a life expectancy of 7 years in 66% of patients.¹⁰ In this case, the patient was in a good condition; thus, the chosen regimen was BDR for 5 cycles. As of this writing, the patient has undergone 2 cycles of BDR. Protein electrophoresis evaluation after the first cycle showed improved results and normal blood viscosity.

Most of the patients die from WM with a life expectancy of 5 years. Age, hemoglobin, serum albumin, and microglobulin levels were suggested as predictors of WM,^{11,12} whereas IgM levels showed no prognostic value.¹² The 2006 International Prognostic Scoring System suggests risk stratification with age > 65 years, macroglobulin > 3mg / L, monoclonal protein > 7g / dL, Hb <11.5 g/dL, and platelets <100x10⁹/L. Having 1 of the aforementioned criteria, except age, is classified as low risk and having >2 criteria is classified as high risk (Table 1).^{9,13} The patient had 3 prognosis factors, including age of above 65 years, suggesting that the patient had high risk of WM.

CONCLUSION

A 67-year-old woman experienced recurrent anemia and extremities swelling. The diagnosis to determine the etiology of the disease was challenging. After many investigations including BMA, protein serum analysis, and immunophenotypes, the patient was finally diagnosed with Waldenström macroglobulinemia. The patient showed atypical initial symptoms such as recurrent anemia and did not have diabetes. The differential diagnoses have also been ruled out one by one so that the

patient can be treated appropriately. The patient had a high prognosis for mortality.

PATIENT CONSENT

The patient had agreed and signed informed consent regarding publishing this clinical case in an academic journal without exposing the patient's identity.

ACKNOWLEDGMENTS

We would like to thank to patient.

DISCLOSURE OF CONFLICTS OF INTEREST

The authors declare no conflict of interest regarding the manuscript.

FUNDING

None.

AUTHOR CONTRIBUTION

All authors contributed equally to the study.

REFERENCES

1. Teras LR, DeSantis CE, Cerhan JR, Morton LM, Jemal A, Flowers CR. 2016 US lymphoid malignancy statistics by World Health Organization subtypes. *CA Cancer J Clin.* 2016;66(6):443-59.
2. Monge J, Braggio E, Ansell SM. Genetic factors and pathogenesis of Waldenström's macroglobulinemia. *Curr Oncol Rep.* 2013;15(5):450-6.
3. Kastiris E, Leblond V, Dimopoulos MA, Kimby E, Staber P, Kersten MJ, et al. Waldenström's macroglobulinaemia: ESMO Clinical Practice Guidelines for diagnosis, treatment and follow-up. *Ann Oncol.* 2018;29:iv41-iv50.
4. Owen RG, editor Developing diagnostic criteria in Waldenström's macroglobulinemia. *Semin Oncol.* 2003; Elsevier.

5. Gertz MA. Waldenström macroglobulinemia treatment algorithm 2018. *Blood Cancer J.* 2018;8(4):1-7.
6. Ansell SM, Kyle RA, Reeder CB, Fonseca R, Mikhael JR, Morice WG, et al., editors. Diagnosis and management of Waldenström macroglobulinemia: Mayo stratification of macroglobulinemia and risk-adapted therapy (mSMART) guidelines. *Mayo Clinic Proceedings*; 2010: Elsevier.
7. Swerdlow S, Cook J, Sohani A, Pileri S, Harris N, Jaffe E. Lymphoplasmacytic Lymphoma in WHO Classification of Tumours of Haematopoietic and Lymphoid Tissues. *WHO.* 2017:232-5.
8. Vijay A, Gertz MA. Waldenström macroglobulinemia. *Blood, The Journal of the American Society of Hematology.* 2007;109(12):5096-103.
9. Gertz MA. Waldenström macroglobulinemia: 2019 update on diagnosis, risk stratification, and management. *Am J Hematol.* 2019;94(2):266-76.
10. Dimopoulos MA, Tedeschi A, Trotman J, García-Sanz R, Macdonald D, Leblond V, et al. Phase 3 trial of ibrutinib plus rituximab in Waldenström's macroglobulinemia. *New Engl J Med.* 2018;378(25):2399-410.
11. Ghobrial IM, Fonseca R, Gertz MA, Plevak MF, Larson DR, Therneau TM, et al. Prognostic model for disease-specific and overall mortality in newly diagnosed symptomatic patients with Waldenström macroglobulinaemia. *Br J Haematol.* 2006;133(2):158-64.
12. Dimopoulos MA, Gika D, Zervas K, Kyrtonis MC, Symeonidis A, Anagnostopoulos A, et al. The international staging system for multiple myeloma is applicable in symptomatic Waldenström's macroglobulinemia. *Leuk Lymphoma.* 2004;45(9):1809-13.
13. Morel P, Duhamel A, Gobbi P, Dimopoulos MA, Dhodapkar MV, McCoy J, et al. International prognostic scoring system for Waldenström macroglobulinemia. *Blood.* 2009;113(18):4163-70.



This work is licensed under a Creative Commons Attribution