

Neonatal varicella: a rare case



CrossMark

Nanda Earlia^{1,2*}, Wahyu Lestari^{1,2}, Fitri Dewi Ismida^{3,4}, Annisa Amalia¹, Aqil Yuniawan Tasrif¹, Mikyal Bulqiah¹, Dea Silvia Ramadana¹

¹Dermatology Department, School of Medicine, Universitas Syiah Kuala, Banda Aceh, Aceh, Indonesia;

²Dermatology Department, dr. Zainoel Abidin General Hospital, Banda Aceh, Aceh, Indonesia;

³Anatomical Pathology Department, School of Medicine, Universitas Syiah Kuala, Banda Aceh, Aceh, Indonesia;

⁴Anatomical Pathology Department, dr. Zainoel Abidin General Hospital, Banda Aceh, Aceh, Indonesia;

*Corresponding author:
Nanda Earlia;

Dermatology Department, School of Medicine, Universitas Syiah Kuala, Banda Aceh, Aceh, Indonesia;

nanda.earlia@unsyiah.ac.id

Received: 2022-12-28

Accepted: 2022-04-16

Published: 2022-04-30

ABSTRACT

Introduction: Varicella-zoster virus (VZV) infection in pregnant women in the last three weeks of pregnancy or the days before delivery causes neonatal varicella. It is rare in newborns and infants due to passive immunity received from the mother. Thus we report a rare case of neonatal varicella for an educational purpose.

Case report: A 14-day-old girl was referred to the Department of Pediatrics with a red rash all over her body. The red rash begins on the face and subsequently spreads across the body fever for four days before the appearance of the rash. During the third trimester of pregnancy, the patient's mother had varicella. The patient was delivered vaginally by the midwife at full term, weighing 3,400 g. Macules, papules, pustules, and vesicles, multiple in number, distinct, miliary to guttate in size, and universal distribution, were identified on physical examination in the facial, thoracic, and upper extremities region et inferior bilaterally. The Tzank test found multinucleated giant cells. Skin biopsy found stratum spinosum edema with powdered lymphocyte inflammatory cells (typical for varicella). Treatment with intravenous acyclovir showed improvement after 5 days.

Conclusion: VZV generates a wide spectrum of clinical symptoms in the fetus and newborn and can be a life-threatening condition. Early recognition of pregnant women and newborns who are at risk for VZV infection is very necessary so that prophylaxis and treatment can be started immediately.

Keywords: Acyclovir, neonatal varicella, pregnancy.

Cite This Article: Earlia, N., Lestari, W., Ismida, F.D., Amalia, A., Tasrif, A.Y., Bulqiah, M., Ramadana, D.S. 2022. Neonatal varicella: a rare case. *Bali Medical Journal* 11(1): 495-498. DOI: 10.15562/bmj.v11i1.3060

INTRODUCTION

Varicella Zoster virus (VZV) is part of the herpesvirus family and is the cause of both varicella and herpes zoster.¹ Varicella during pregnancy is a rare condition but has serious potential to develop into severe disease for the mother and fetus.² Primary maternal infection can cause clinical manifestations in both the fetus and neonate. There are 3 forms of varicella zoster infection that can involve the fetus and neonate: congenital varicella syndrome, perinatal varicella, and neonatal varicella infection.³ Varicella are transmitted to the fetus through the transplacental route, infection during delivery or respiratory droplets or direct contact with infectious lesions after birth.⁴

Neonatal varicella occurs due to varicella zoster virus infection experienced by pregnant women in the last 3 weeks of pregnancy or the days before delivery. Manifestations in infants will appear shortly before delivery up to 10 to 12 days after birth.⁵ Clinical appearance on

the skin that can be found is a centripetal rash (starting on the trunk and spreading to the face and extremities), starting with erythematous macules and progressing to vesicles and rupture to form crusts. The diagnosis of varicella is based on clinical findings on the skin. However, other investigations can also be carried out.⁶

Varicella in pregnant women experienced during pregnancy at term or immediately after delivery, can cause severe morbidity in neonates. Infected infants may show skin lesions, but pneumonia, hepatitis, meningoencephalitis and disseminated intravascular coagulation (DIC) may also be presented.⁷

CASE REPORT

A baby girl, 14 days old, was consulted from the Pediatric Department with a red rash complaint all over her body. The patient was referred from a regional hospital with complaints of spots all over the body and shortness of breath and was diagnosed with varicella neonatorum and

respiratory distress. Initially, the family brought the patient to the regional hospital with complaints of a red rash all over the body accompanied by shortness of breath that appeared at the age of 10 days. The red rash initially starts on the face and then spreads all over the body. History of fever from 4 days to the day before the rash first appeared. The patient was born from a mother who was suffering from varicella zoster and at home, the patient was in close contact with his two siblings who were suffering from the same disease. At 38-39 weeks of gestation, the patient's mother had contact with her child who had just returned from the Islamic boarding school due to chickenpox. At that time, some of his son's friends also had chickenpox. The patient's mother had complained of fever for about 2 days before the reddish rash appeared. A reddish rash appeared 2 days before the patient's born. Allergy history was denied. The patient's born when her mother still had a reddish rash. When at home, the patient is given breast milk by

first pumping it with a pump. There is no history of autoimmune/genetic diseases in the family such as bullous disease.

Obstetric history of the patient's mother, G5P4A0, with the first day of the last menstrual period (LMP) at the end of January. History of giving birth to the first to fourth children vaginally by a midwife without any complications. History of using 1 month injectable contraceptives and contraceptive pills. The patient was born at term in the midwife vaginally with a birth weight of 3,400 g. The mother had routine antenatal care (ANC) at the midwife 7 times and at the doctor 3 times during pregnancy. Ultrasonography (USG) results, the fetus is said to be normal.

The physical examination found that the facial, thoracic and superior and inferior dextra et sinistra regions, macules, papules, pustules and vesicles were seen, multiple, discrete in number miliary to guttate size, and universal distribution. Then a supporting examination in the form of a Tzank test was carried out, the results obtained were multinucleated giant cells. Another examination carried out was a skin biopsy, the results obtained were the finding of stratum spinosum edema with powdered lymphocyte inflammatory cells (typical for varicella).

The patient was diagnosed with neonatal varicella and admitted to a neonatal intensive care unit. The patient was given systemic therapy (injection of acyclovir 70 mg every 8 hours) and topical therapy (chloramphenicol ointment, mupirocin ointment) and compresses with normal saline 0.9%.

DISCUSSION

This is a case report of neonatal varicella in an infant aged 14 days. The diagnosis is made based on the results of the history, physical examination and supporting examinations in the Tzank test and skin biopsy. The case of neonatal varicella infection in this patient is rare. In Australia, 44 cases of neonatal varicella (1:17,000 pregnancies per year) were recorded in 1995-1997.⁸ Based on surveillance data in 2006-2009, the incidence of neonatal varicella is 0.7 per 100,000 live births annually.⁹ In a study conducted by Michele Trotta et al., the incidence of congenital varicella syndrome was 1.56%.¹⁰ In this

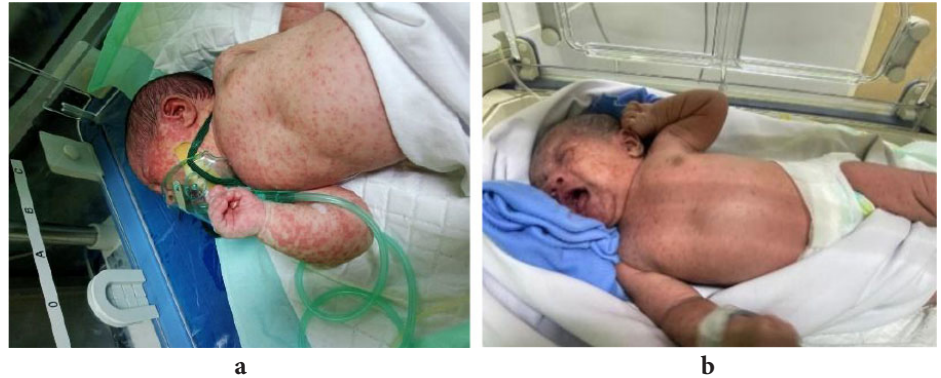

Figure 1. a. First day patient in the Emergency Room; b. Patient after being treated for 5 days in NICU.

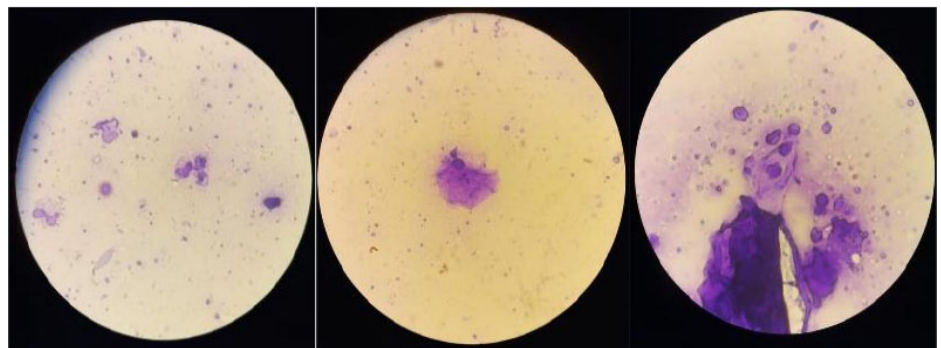


Figure 2. Tzank test : multinucleated giant cells.

case, the onset of symptoms that appears in the patient's mother becomes one of the important factors in determining the patient's prognosis.

When first consulted to the Department of Dermatology and Venereology, the patient showed clinical criteria obtained from history and physical examination suggesting varicella zoster infection. The clinical presentation of varicella is an erythematous macular rash that develops rapidly and turns into papules, vesicles and pustules. Therefore it will appear a picture of a multiform lesion. Usually the spread of this rash is centripetal, or starts from the middle of the body and spreads to the face and extremities.^{5,11} Based on the clinical appearance, this case can be differentially diagnosed with several transient neonatal skin disorders, namely varicella-like disorders which are caused by changes in the baby's environment from intrauterine to extrauterine, for example a dry and aerobic environment. The first differential diagnosis is transient neonatal pustular melanosis, which is a condition where vesicopustular lesions can be seen

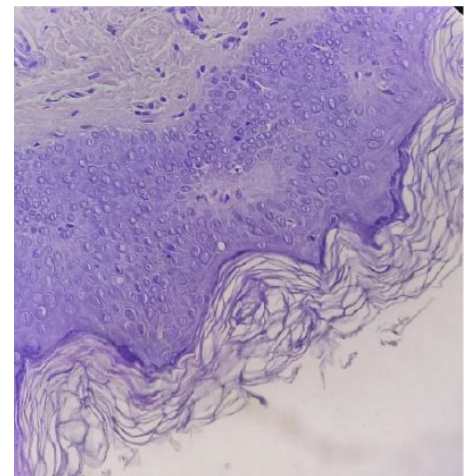


Figure 3. Skin biopsy result : multinucleated giant cells.

on the chin, forehead, neck, lower back, buttocks and leg areas. These lesions rupture easily and leave hyperpigmented macules of a collarlet type.^{11,12} Secondly, erythema toxicum neonatorum, is an acute immunological reaction, in which the skin commensal microflora attacks the neonate through the hair follicles. In this

situation, erythematous macules, papules, pustules and vesicles may be found that are about 1-2 mm in size. The eruption usually starts from the middle of the body, face, buttocks.^{11,12}

This patient underwent a Tzank test and a skin biopsy. The Tzank test is a simple, fast and inexpensive test that is useful in establishing a diagnosis. On examination, multinucleated giant cells, syncytia, and ballooning cell degeneration will be found. However, this test has limited sensitivity (only 40-50%).¹³ In addition, a biopsy can also be performed and can provide information regarding the pre-vesicular stage.¹⁴ The definitive diagnosis of VZV infection established by PCR that the sample can be used from vesicular fluid, scabs from crusted lesions, biopsy tissue, or cerebrospinal fluid. Early in the course of the disease with varicella, PCR analysis of saliva and buccal swabs can also detect the virus. PCR is more sensitive than previously utilized diagnostic tests such as viral culture or direct fluorescent antigen assays. It also has the ability to distinguish wild-type vaccines from VZV strains. The VZV IgM test should not be used to confirm or rule out acute infection in a pregnant woman or child.¹¹

In neonates infected with VZV, antivirals such as acyclovir can be given. Acyclovir is the standard therapeutic antiviral agent used to manage VZV infection. However, it should be considered that oral bioavailability is only 15-30%. Varicella in at-risk patients and zoster in immunocompetent patients can be treated orally. In severe VZV infection, especially in immunocompromised patients, acyclovir should be given intravenously (IV). After IV administration of acyclovir, CNS side effects are occasionally encountered, whereas oral drugs may be associated with gastrointestinal side effects. Substances with renal toxicity should not be combined with acyclovir. Laboratory renal and hepatic parameters should be monitored.¹⁵

Acyclovir therapy for infants/children at a dose of 10-20 mg/kg body weight (maximum 800 mg/day) every 6 hours for 7 days. If there are signs of secondary bacterial infection, antibiotics may be given.¹⁵ Breastfeeding is recommended for newborns exposed to varicella infection

because antibodies in breast milk may be protective. Breastfeeding is recommended regardless of the mother's immune status. Breastfeeding is believed to transmit the virus, so breast milk (ASI) should be given by pumping it first and ensuring no lesions around the breast.¹⁶

Administration of varicella zoster immunoglobulin after exposure is required in some conditions.^{11,17} Varicella immunization is recommended for all women who are not immune to VZV as part of prenatal and postpartum care.^{11,17} Vaccines varicella should not be given to pregnant women, because of the possible effects on fetal development. In women who have recently received VZV vaccination, pregnancy should be delayed at least 1 month after vaccination.¹⁷ Maternal primary VZV infection in the third trimester can cause maternal pneumonia with significant morbidity and mortality. Complications of neonatal varicella can include low birth weight (LBW), cutaneous aplasia, cataracts, microphthalmia, chorioretinitis, bone hypoplasia, neurological abnormalities, mental retardation, microcephaly, hydrocephalus, cerebellar aplasia, encephalomyelitis, dorsal radiculitis and urethral and anal sphincter dysfunction.^{18,19} At the age of 14 days, this patient got neonatal varicella. Within the first four days following birth, neonatal chickenpox is frequently found to be moderate. If neonatal chickenpox strikes between the ages of 5 and 10 to 12 days, 23 percent of cases result in death.²⁰

The limitation of this case is Polymerase chain reaction (PCR) examination was not carried out because it was not available at the hospital.

CONCLUSION

We reported a rare case of neonatal varicella on 14 days old girl. Treatment with intravenous acyclovir showed improvement after 5 days. VZV can cause a wide spectrum of clinical manifestations in the fetus and neonate. Although some consider it a benign childhood disease, VZV can be a life-threatening disease. Early recognition of pregnant women and neonates at risk for VZV infection may prompt prophylaxis and treatment.

CONFLICT OF INTEREST

The authors declare that there is no conflict of interest regarding the manuscript.

FUNDING

The authors are responsible for the funding without the involvement of grant, sponsorship, or any other funding sources.

AUTHOR CONTRIBUTION

All authors are contributed equally to the content of the study.

ETHICAL STATEMENT

The informed consent was declared from patient's parent regarding the publication in this journal.

REFERENCES

1. Silverman RA, Boos MD. The Exanthematous Diseases of Childhood. In: Paller AS, Mancini AJ, editors. *Hurwitz Clinical Pediatric Dermatology: A Textbook of Skin Disorders of Childhood and Adolescence*. 5th ed. New York: Elsevier; 2012.
2. Blumental S, Lepage P. Management of varicella in neonates and infants. *BMJ Paediatrics Open*. 2019;3(1):1-6.
3. Kulhan M, Kulhan NG, Nayki UA, Nayki C, Ulug P. Case Report Varicella infections during pregnancy and literature review : A case report. 2017;4(1):11-4.
4. Nurhayati RH. Manajemen Varisela Neonatal. *Cermin Dunia Kedokteran* [Internet]. 2020;46(11):672-4. Available from: <http://103.13.36.125/index.php/CDK/article/view/408>
5. Straus SE, Oxman MN, Schmader KE. Varicella and Herpes Zoster. In: *Fitzpatrick's Dermatology In General Medicine*. 2nd ed. Philadelphia: Mc Graw Hill Education Medical; 2017. p. 1885.
6. Kennedy PGE, Gershon AA. Clinical features of varicella-zoster virus infection. *Viruses*. 2018;10(11):1-11.
7. Ahn KH, Park YJ, Hong SC, Lee EH, Lee JS, Oh MJ, et al. Congenital varicella syndrome: A systematic review. *Journal of Obstetrics and Gynaecology*. 2016;36(5):563-6.
8. Neo AGE, Choi EH, Chokephaibulkit K, Choudhury J, Kuter B, Lee P-I, et al. Burden of varicella in the Asia-Pacific region: a systematic literature review. *Expert Review of Vaccines* [Internet]. 2019; Available from: <https://doi.org/10.1080/14760584.2019.1594781>
9. Lai JW, Ford T, Cherian S, Campbell AJ, Blyth CC. Case Report: Neonatal Varicella Acquired From Maternal Zoster. *Frontiers in Pediatrics*. 2021;
10. Trotta M, Borchì B, Niccolai A, Venturini E, Giachè S, Sterrantino G, et al. Epidemiology, management and outcome of varicella in

- pregnancy: a 20-year experience at the Tuscany Reference Centre for Infectious Diseases in Pregnancy. *Infection* [Internet]. 2018;46(5):693–9. Available from: <http://dx.doi.org/10.1007/s15010-018-1150-4>
11. Petersen R, Miller AS. Varicella zoster virus infection in neonates. *NeoReviews*. 2016;17(9):e507–14.
 12. Queirós C, Santos MC, Pimenta R, Filipe P. Transient Cutaneous Alterations of the Newborn. *European Medical Journal*. 2021;6(1):97–106.
 13. De Paschale M, Clerici P. Microbiology laboratory and the management of mother-child varicella-zoster virus infection. *World Journal of Virology*. 2016;5(3):97.
 14. Bergqvist C, Abi Aad Y, Nassar D, El Zein S, Kanj SS. Disseminated herpes simplex virus and varicella zoster virus co-infection in a patient with idiopathic thrombocytopenic purpura. *Journal of Infection and Public Health* [Internet]. 2019;12(3):438–41. Available from: <https://doi.org/10.1016/j.jiph.2018.08.010>
 15. Sauerbrei A. Diagnosis, antiviral therapy, and prophylaxis of varicella-zoster virus infections. *European Journal of Clinical Microbiology and Infectious Diseases* [Internet]. 2016;35(5):723–34. Available from: <http://dx.doi.org/10.1007/s10096-016-2605-0>
 16. Vancea G, Calistru PI, Ceausu E. Varicella-zoster Virus Infection in Pregnancy. *Romanian Journal of Infectious Diseases*. 2018;21(3):96–104.
 17. Lachiewicz AM, Srinivas ML. Varicella-zoster virus post-exposure management and prophylaxis: A review. *Preventive Medicine Reports* [Internet]. 2019;16(November):101016. Available from: <https://doi.org/10.1016/j.pmedr.2019.101016>
 18. Singh M, Breuer J. Varicella zoster virus infections. In: *Viral Infections of the Human Nervous System*. 2013. p. 87–114.
 19. Cherukuri N, Lingaldinna S, Anjum S, Singh H. Congenital varicella syndrome in a neonate. Vol. 6, *Indian Journal of Child Health*. 2019. p. 142–3.
 20. Sauerbrei A, Wutzler P. Neonatal varicella. *Journal of Perinatology*. 2001;21(8):545–9.



This work is licensed under a Creative Commons Attribution