



Published by DiscoverSys

# Hypertensive emergency: an overview of heart as target organ damage



CrossMark

Starry Homenta Rampengan<sup>1\*</sup>, H J Sunarto<sup>2</sup>

## ABSTRACT

Hypertension is currently still a global problem in the cardiology and vascular fields with an increasing trend. One of the emergency conditions related to an increase in blood pressure is emergency hypertension. Emergency hypertension is a condition where blood pressure rises rapidly and severely, resulting in new or progressive organ damage. Symptoms can range from chest pain, shortness of breath to delirium. The heart is one of the organs that can be damaged by hypertensive emergencies. The availability and demand for oxygen from the coronary blood vessels to the heart muscle cells will experience an imbalance due to a sudden increase in blood pressure. Lack of oxygen that occurs can cause heart muscle

cells' death affected heart structure and its function. The symptoms that appear can be in the form of acute coronary syndrome or acute heart failure. Some modalities can detect heart structure changes, like electrocardiography for general and echocardiography for specific examination. Hypertensive emergencies can be treated by several rapid-acting antihypertensive agents, which can be selected based on the clinical manifestations. As the symptoms related to heart damage are acute coronary syndrome and acute heart failure, so the treatment will be specific, respectively. Good knowledge related to emergency hypertension management and early treatment will reduce patient morbidity.

**Keywords:** hypertensive emergency, heart, organ damage

**Cite this Article:** Rampengan, S.H., Sunarto, H.J. 2020. Hypertensive emergency: an overview of heart as target organ damage. *Bali Medical Journal* 9(3): 903-906. DOI: [10.15562/bmj.v9i3.2174](https://doi.org/10.15562/bmj.v9i3.2174)

<sup>1</sup>Department of cardiology, Prof R. D. Kandou Hospital, Faculty of Medicine, Universitas Sam Ratulangi, Manado, Indonesia

<sup>2</sup>Resident of cardiology, Faculty of Medicine, Universitas Sam Ratulangi, Manado, Indonesia

## BACKGROUND

Hypertension is still a global health problem, including in Indonesia, because of its high prevalence. Nearly 1 billion people in the world experience hypertension and this number will continue to increase every year, especially in the elderly population.<sup>1-3</sup> Results of primary health research (*Riskesdas*) Indonesia from year to year, there is a significant increase in hypertension sufferers. In 2018 amounting to 34.1%.<sup>4</sup> Hypertension emergencies is a condition of a sudden increase in blood pressure by one or more target organ damage.<sup>1,2,4-15</sup>

One of the target organs that can be damaged is the heart.<sup>4-15</sup> The heart's damage will cause an imbalance in demand and oxygen availability from the coronary vessels to the heart muscle cells. This imbalance will result in heart muscle cells' death resulting in acute coronary syndrome and acute heart failure.<sup>1,2</sup> Attention is needed in pathomechanism and management of a hypertensive emergency, especially on heart organ damage.

increase in systolic blood pressure >180mmHg and diastolic blood pressure >120 mmHg accompanied by target organ damage. The organ damage that is often affected is the brain, eyes, heart, kidneys and blood vessels.<sup>2,4-15</sup> Hypertension that is chronic with irregular or inadequate treatment has the potential to become hypertensive emergencies. Part of the hypertensive crisis, where blood pressure increases suddenly, must be managed as soon as possible so that further damage does not occur.<sup>2</sup>

## Sign and Symptoms

Emergency hypertension is characterized by acute organ damage accompanied by blood pressure above 180/120 mmHg. Some of the signs and symptoms that need to be considered in hypertensive emergencies are chest pain (location, quality, radiation and duration), shortness of breath, acute changes in mental status, headache, nausea, vomiting, and blurry eyes. Stroke and hypertensive encephalopathy can be obtained in the cerebrovascular. Also, acute heart failure symptoms (leg edema, hepatojugular reflex, murmur) and aortic dissection (different blood pressure reading).<sup>6,8</sup>

Physical examination should look for acute signs of hypertensive emergencies, including increased jugular venous pressure, rhonchi sound, gallops,

\*Corresponding to:  
Starry Homenta Rampengan;  
Department of cardiology, Prof  
R. D. Kandou Hospital, Faculty  
of Medicine, Universitas Sam  
Ratulangi, Manado, Indonesia;  
[starry8888@yahoo.com](mailto:starry8888@yahoo.com)

## OVERVIEW OF HYPERTENSIVE EMERGENCY

### Definition and Risk Factor

Emergency hypertension is defined as a sudden

Received: 2020-09-08  
Accepted: 2020-11-15  
Published: 2020-12-01

$$MAP = CO \times SVR$$

$$MAP = \frac{(SBP - DBP) + DBP}{3}$$

$$MAP = \frac{2 \times DBP + SBP}{3}$$

$$SVR = \frac{80 \times (MAP - MVP)}{CO}$$

Note:

MAP: Mean Arterial Pressure

CO: Cardiac Output

SVR: Systemic Vascular Resistance

SBP: Systolic Blood Pressure

DBP: Diastolic Blood Pressure

MVP: Mean Vein Pressure

**Figure 1.** The formula of mean arterial pressure and systemic vascular resistance

fourth heart sound, murmurs, ascites hepatomegaly and edema of the whole body. Measurement of mean arterial blood pressure (MAP) on the right and left sides of the body can be performed if aortic dissection or aortic coarctation is suspected (Figure 1).<sup>2,7</sup>

### General Treatment

Several rapid-acting antihypertensive agents are available to treat hypertensive emergencies. The choice of these drugs is selected based on the clinical manifestations of target organ damage. Clinicians must know about frequently used drugs, potential clinical scenarios in which they can be used most effectively, and a side effect/risk profile for each of these drugs to initiate therapy successfully.<sup>7</sup>

In general, the target of lowering blood pressure is based on the principle of autoregulation, namely a decrease in the mean arterial blood pressure of no more than 20-25% in the first 1 hour, then from 160/100 to 110 mmHg in 2 - 6 hours later. If the patient's condition is stable, the target of lowering blood pressure to normal can be achieved within 24-48 hours.<sup>12</sup>

## HEART AS AN ORGAN DAMAGE IN HYPERTENSIVE EMERGENCY

### Pathomechanism of Hypertensive Emergency on Heart

A prolonged increase in blood pressure can precede a sudden increase in blood pressure in hypertensive emergencies. An increase in blood pressure that reaches a critical level stimulates a vascular response increasing the resistance.<sup>8</sup> Myogenic vascular response provoked by increased intravascular pressure is vasoconstriction. The periphery's relative hypoperfusion exacerbates this situation by stimulating the release of vasoactive hormones such as angiotensin-II, norepinephrine, endothelin, and antidiuretic hormone. The sudden increase in systemic vascular resistance is the cause

of the hypertensive crisis.<sup>8</sup>

This sudden increase can cause vascular damage, resulting in platelet activation and the coagulation cascade, deposits of fibrin, and induction of oxidative stress and proinflammatory cytokines. Production of NO is interrupted. That results in tissue ischemia and vascular lesions from fibrinoid necrosis of the arterioles and other small arteries. The vascular damage will then result in low perfusion, extravasation of fluids and tissue ischemia. The cascade of these events is caused by tissue ischemia, which stimulates the release of vasoactive substances, which results in worsening hypertension.<sup>2,7,8</sup>

Organ damage in hypertensive crises occurs due to sudden changes in blood pressure that the target organs cannot compensate for those changes. On the other hand, a chronic increase in blood pressure protects the organs from sudden increases in transmitted pressure due to chronic hypertension-induced arterioles hypertrophy.<sup>6</sup> The organs most commonly affected are the brain, heart, eyes, large arteries and kidneys. With proper treatment, the vasoconstriction-ischemia-vasoconstriction cycle can be stopped.<sup>2,8,9</sup>

Due to hypertensive emergencies, sudden damage to the heart will cause an imbalance in the supply and demand for oxygen from the coronary blood vessels to the heart muscle cells. Those imbalances can result in the heart muscle cells' death, leading to the acute coronary syndrome. Suppose a sudden increase in blood pressure occurs in the aorta. In that case, it can result in a tear in the lining of the aortic intima, allowing shear forces from the bloodstream to tear off the intima from the tunica media and spread along the aorta. In some cases, this can result in bleeding from the aorta. According to the Stanford system, aortic dissections involving the ascending aorta are classified as type A. Those that do not involve the ascending aorta are classified as type B.<sup>1,2</sup>

The heart muscle's compensatory mechanism against excess pressure by hypertrophy of the myocardial muscles resulted in several changes in the heart muscles' structure and function. Hypertrophy of the heart muscles can be divided into two general parts, namely concentric hypertrophy, where there is an increase in the width of the myocardial muscles and eccentric hypertrophy, where there is an increase in the length of the myocardial muscles.<sup>2,10</sup> The cardiac muscle response to this compensation is explained by Laplace's law (Figure 2).<sup>10</sup>

Several diagnostic modalities can be used to detect changes in the structure of the heart. The easiest and cheapest examination that can be done is the examination of heart records or electrocardiography (EKG).<sup>2</sup> A more specific

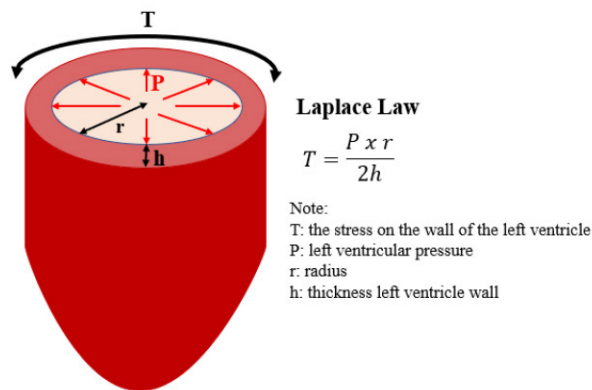
examination is echocardiography. This examination can see the function and structure of the muscle mass of the heart.<sup>1,5,6</sup> Criteria in echocardiography examination uses a reference to the mass of the left ventricular muscle.<sup>17,18</sup> In addition to changes in the heart structure, long-term hypertension can also trigger several severe conditions cardiac emergencies such as acute heart failure, acute coronary syndrome and aortic dissection.<sup>2,4-8</sup>

### Specific Treatment on Heart Organ Damage in Hypertensive Emergency

Commonly in hypertensive emergencies, patients with cardiac damage presented acute coronary syndrome and acute heart failure. Patients with acute coronary syndromes need to lower their target

systolic blood pressure below 140 mmHg within 1 hour, and the diastolic blood pressure maintained at 60 mmHg. Administration of oxygen and morphine can be used according to clinical needs and assessment. The drugs of choice for acute coronary syndrome can be seen in Table 1. Avoid using hydralazine in these patients because it can cause a “rebound” hypertensive effect. Administration of the drug sodium nitroprusside can cause a “stealing” mechanism of coronary flow caused by coronary vasodilation and should be avoided.<sup>7,8,11,12</sup>

Patients with acute heart failure need to lower their systolic blood pressure below 140 mmHg in the first 1 hour with the choice of nitroglycerin and nitroprusside (Table 1). In most cases of acute heart failure, loop diuretics, enalaprilat or hydralazine may still be useful and must avoid the use of beta-blocking drugs. The use of nitroglycerin or other nitrate groups is still widely used today. Side effects that must be considered when giving nitrate group drugs are hypotension, reflex tachycardia, dizziness and redness.<sup>11</sup>



**Figure 2.** The formula of Laplace Law

### CONCLUSION

The hypertensive emergency will usually be followed by organ damage. The symptoms of acute coronary syndrome or acute heart failure are the symptoms that resulted from heart damage due to hypertensive emergency. Early and appropriate acute coronary syndrome or acute heart failure management in the hypertensive emergency condition will reduce patient morbidity.

**Table 1.** Drug of choices for acute coronary syndrome and acute heart failure in the hypertensive emergency.<sup>7,8,11,12</sup>

Acute Coronary Syndrome	
Drug of Choices	Dose and Administration
Nitro-glycerine	10–400 µg/minute intravenous drip with a dose adjustment of 10–20 µg/minute every 5–15 minutes
Labetalol	10–20 mg intravenous bolus followed by drops can be repeated at the same or double dose 10 minutes before the intravenous drip 0.5–10 mg/min IV drip, adjusted every 15 minutes
Esmolol	500–1,000 µg / kg bolus, followed by 100–300 µg / kg / minute intravenous drop, adjusted dose to 50 µg / kg / minute every 5 minutes
Metoprolol	2.5–5 mg intravenously every 5 minutes, with a maximum dose of 15 mg then every 4-6 hours
Nicardipine	5–15 mg/hour IV drip, with an adjusted dose of 2.5 mg/hour every 5–15 minutes depending on the response to drug administration
Acute Heart Failure	
Drug of Choices	Dose and Administration
Nitro-glycerine	10–200 µg/minute intravenous drip with an adjusted dose of 10–20 µg/min every 5–15 minutes
Nitroprusside	0.25-10 µg/kg/min IV drip, dose adjustment by 0.5 µg/kg/min every 5 minutes

**DISCLOSURES****FUNDING**

None

**ETHICAL STATEMENT**

None

**CONFLICT OF INTEREST**

All authors declare no conflict of interest regarding manuscript writing concept drafting and manuscript publishing.

**AUTHOR CONTRIBUTIONS**

All authors contributed from drafting the conceptual framework, writing and publishing the manuscript.

**REFERENCES**

1. Drago J, Williams G, Lilly L. Hypertension. In: Lilly L, editor. *Patophysiology of Heart Disease*. Philadelphia: Wolters Kluwer; 2016. p. 310–33.
2. Isman F. Krisis Hipertensi. In: Rilantono L, editor. *Penyakit Kardiovaskular (PKV)*. Jakarta: Balai Penerbit FKUI; 2016. p. 263–75.
3. Pertiwi GAR, Aryawangsa AAN, Prabawa IPY, Manuaba IBAP, Bhargah A, Ratni NWS, et al. Factors associated with visit-to-visit variability of blood pressure in hypertensive patients at a Primary Health Care Service, Tabanan, Bali, Indonesia. *Fam Med Community Heal*. 2018;6(4):191 LP – 199. Available from: <http://fmch.bmj.com/content/6/4/191.abstract>
4. Kementerian Kesehatan RI. Hasil Utama RISKESDAS. Jakarta: Badan Litbangkes; 2018.
5. Victor R, Libby P. Systemic Hypertension. In: Braunwald's *Heart Disease*. Philadelphia: Elsevier; 2019. p. 928–56.
6. Williams B, Mancia G, Spiering W, Agabiti Rosei E, Azizi M, Burnier M, et al. 2018 ESC/ESH Guidelines for the management of arterial hypertension: The Task Force for the management of arterial hypertension of the European Society of Cardiology (ESC) and the European Society of Hypertension (ESH). *Eur Heart J*. 2018;39(33):3021–104.
7. Suneja M, Sanders ML. Hypertensive emergency. *Med Clin*. 2017;101(3):465–78.
8. Brathwaite L, Reif M. Hypertensive emergencies: a review of common presentations and treatment options. *Cardiol Clin*. 2019;37(3):275–86.
9. Longo D, Harrison T. *Harrison's principles of internal medicine*. 18th ed. New York: McGraw-Hill; 2012.
10. Cucci MD, Benken ST. Blood pressure variability in the management of hypertensive emergency: A narrative review. *J Clin Hypertens*. 2019;21(11):1684–92.
11. Carey RM, Whelton PK. Prevention, detection, evaluation, and management of high blood pressure in adults: synopsis of the 2017 American College of Cardiology/American Heart Association Hypertension Guideline. *Ann Intern Med*. 2018;168(5):351–8.
12. Peixoto AJ. Acute severe hypertension. *N Engl J Med*. 2019;381(19):1843–52.
13. Nadruz W. Myocardial remodeling in hypertension. *J Hum Hypertens*. 2015;29(1):1–6.
14. Mozaffarian D, Benjamin EJ, Go AS, Arnett DK, Blaha MJ, Cushman M, et al. Executive summary: heart disease and stroke statistics—2016 update: a report from the American Heart Association. *Circulation*. 2016;133(4):447–54.
15. González A, Ravassa S, López B, Moreno MU, Beaumont J, San José G, et al. Myocardial remodeling in hypertension: toward a new view of hypertensive heart disease. *Hypertension*. 2018;72(3):549–58.
16. Papadopoulos DP, Sanidas EA, Viniou NA, Gennimata V, Chantziara V, Barbetseas I, et al. Cardiovascular hypertensive emergencies. *Curr Hypertens Rep*. 2015;17(2):5.
17. Zhang W, Zhou Y, Bai B, Yu S, Xiong J, Chi C, et al. Consistency of left ventricular hypertrophy diagnosed by electrocardiography and echocardiography: the Northern Shanghai Study. *Clin Interv Aging*. 2019;14:549.
18. Lang RM, Badano LP, Mor-Avi V, Afilalo J, Armstrong A, Ernande L, et al. Recommendations for cardiac chamber quantification by echocardiography in adults: an update from the American Society of Echocardiography and the European Association of Cardiovascular Imaging. *Eur Hear Journal-Cardiovascular Imaging*. 2015;16(3):233–71.



This work is licensed under a Creative Commons Attribution