



Published by DiscoverSys

## Tracheostomy in upper airway obstruction on a COVID-19 patient

Rohaizam Japar Jaafar<sup>1</sup>, Zakinah Yahaya<sup>1</sup>, Mohd Razif Mohamad Yunus<sup>2</sup>,  
Marina Mat Baki<sup>2\*</sup>



CrossMark

### ABSTRACT

**Background:** Stridor due to upper airway obstruction in a COVID-19 positive patient is a big challenge to the medical team, especially anesthetists and otolaryngologists. In this condition, performing aerosol-generating procedures (AGP) is time-sensitive and increases virus transmission risk. The dilemma of treating a stridorous patient with laryngeal carcinoma and concurrent COVID-19 positive with pneumonia is possibly become a new normal in this era.

**Case Report:** A 66-year-old male, chronic smoker, completed six days of in-patient treatment for community-acquired pneumonia when the RT-PCR for COVID-19 was found to be negative. He was seen in the otorhinolaryngology (ORL) clinic two weeks later due to hoarseness for two months associated with worsening shortness of breath and cough. He had soft stridor at rest and was mildly tachypnoeic. Flexible endoscopy revealed a mass on the right immobile vocal cord with a small glottic airway. A repeat nasopharyngeal swab for COVID-19 on the same day was positive.

A detailed discussion involving a multidisciplinary team lead to the decision to secure the patient's airway by first intubating him with a small endotracheal tube and followed by tracheostomy in the same setting. Here, the experience in managing upper airway obstruction due to laryngeal carcinoma (at least T3) in a patient with stage 4 COVID-19 is presented and discussed. The challenges emerged due to the inevitable series of AGPs that need to be performed. Multidisciplinary team involvement comprises ORL surgeon, anesthetist, infectious disease, and respiratory physician is pertinent.

**Conclusion:** This is the first case in the literature on a stridorous COVID-19 positive patient with laryngeal carcinoma that requires emergency tracheostomy. The case highlights the challenges and decision-making in managing such cases that are supposed to be straightforward before the COVID-19 pandemic era. This shall be the new normal for otorhinolaryngologists, anesthetists, and maybe any other specialties who deal with AGPs.

**Keywords:** stridor, upper airway obstruction, tracheostomy, COVID-19, SARS-COV-2

**Cite this Article:** Jaafar, R.J., Yahaya, Z., Yunus, M.R.M., Baki, M.M. 2020. Tracheostomy in upper airway obstruction on a COVID-19 patient. *Bali Medical Journal* 9(3): 806-810. DOI: [10.15562/bmj.v9i3.1903](https://doi.org/10.15562/bmj.v9i3.1903)

### BACKGROUND

World Health Organisation (WHO) declared COVID-19 a worldwide pandemic on the 11<sup>th</sup> March 2020.<sup>1</sup> As the Covid-19 outbreak spreads, Malaysia recorded one of the highest numbers of confirmed cases in Southeast Asia. We are taking a hard hit by more than 6535 confirmed cases at this time of writing, with 107 deaths in two months.<sup>2</sup> This virus infection is mainly transmitted by droplets that the spread is gravity-based or due to fomite contamination.<sup>3</sup> The main human body part that is the most shedding the virus is the nasal cavity. Therefore, the specimen RT-PCR test sampling is recommended to be taken from the nasopharynx or the deep oropharynx by throat washing.<sup>4</sup>

However, the virus can be in a smaller particle when aerosol-generating procedures (AGP) involved airway mucosal manipulation such as tracheostomy, intubation, laryngoscopy, and bronchoscopy.<sup>3,5</sup> COVID-19 virus in the aerosol may remain suspended in the air for up to 3 hours.<sup>5</sup> This may be why doctors who were infected by

COVID-19 are among those who have been doing these AGPs regularly.<sup>3</sup> This virus infected many otolaryngologists, anesthetists, critical care doctors, and ophthalmologists in Wuhan, China.<sup>6</sup> Moreover, the first reported fatality in the U.K. doctor is an otolaryngologist.<sup>7</sup>

Therefore, performing AGPs during this pandemic is undergoing a paradigm shift.<sup>5</sup> The selection of patients and decisions on the execution of the procedure has to be done deliberately. Attending a patient with upper airway obstruction with a concurrent positive COVID-19 test is highly challenging. Publications on case reports or case series of COVID-19 patients are numerous. To the authors' knowledge, none had reported a stridor case due to laryngeal carcinoma in a COVID-19 positive patient with pneumonia. Here, such a case that is necessitating tracheostomy is presented, and the authors discussed issues related to diagnosis, prognosis, and decision to secure the airway in a stridorous patient with concurrent lower airway problems.

<sup>1</sup>Department of Otorhinolaryngology, Hospital Kuala Lumpur, Kuala Lumpur, Malaysia

<sup>2</sup>Department of Otorhinolaryngology, Universiti Kebangsaan Malaysia Medical Centre, Hospital Canselor Tuanku Muhriz, UKM, Malaysia

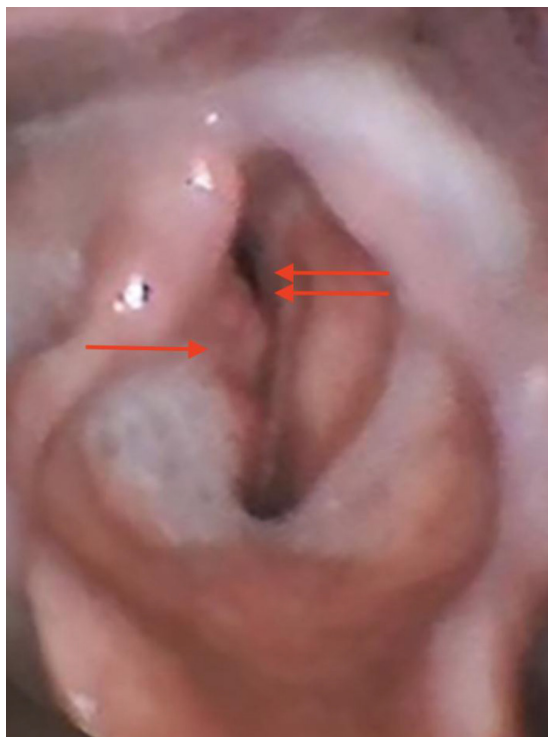
\*Corresponding to:  
Marina binti Mat Baki;  
Department of Otorhinolaryngology, Universiti Kebangsaan Malaysia Medical Centre, Faculty of Medicine, Hospital Canselor Tuanku Muhriz; [marinamatbaki@ppukm.ukm.edu.my](mailto:marinamatbaki@ppukm.ukm.edu.my)

Received: 2020-07-11  
Accepted: 2020-10-22  
Published: 2020-12-01

## CASE REPORT

A 66-year-old male who is a chronic smoker was admitted to a severe acute respiratory infection (SARI) ward for worsening shortness of breath for two weeks associated with cough and hoarseness for two months. His chest X-ray showed bilateral lower zone ground-glass changes, and right pleural effusion with left lower lobe segmental consolidation, and the sputum grew *Klebsiella pneumoniae*. The sputum for acid-fast bacilli (AFB) and oronasopharyngeal swab for COVID reverse transcriptase-polymerase chain reaction (RT-PCR) was negative. He was treated for community-acquired pneumonia and was sent home after completing intravenous Augmentin and Azithromycin one week later.

He was seen at the otorhinolaryngology (ORL) outpatient clinic for his symptoms of chronic hoarseness. The thin built patient at the clinic revealed that he felt that the breathlessness has not improved since the hospital discharge apart from worsening hoarseness. Besides, he also had noisy breathing on exertion, occasional aspiration symptoms, dysphagia, loss of appetite, and weight loss. When he was talking, soft



**Figure 1.** A fungating mass at right false cords, obliterating Morgagni's sinus, and the right true cord (arrow). The anterior commissure was involved, and right true cord was fixed. The laryngeal inlet was small (double arrow), and a laryngeal penetration with own saliva was observed.

stridor was perceivable. There were no neck masses or cervical lymphadenopathy. Flexible nasopharyngolaryngoscopy (FNPLS) revealed a fungating mass at the right false cords, obliterating Morgagni's sinus down to the right true cord. The mass also involved the anterior commissure, and the right vocal cord was immobile. The laryngeal inlet was small and laryngeal penetration with saliva was observed (Figure 1). Hence, a clinical diagnosis of laryngeal carcinoma was made with at least T3 tumor staging. According to the hospital guidelines, the doctor who attended the patient donned a full personal protective equipment (PPE), including an N95 mask, head cover, fluid-repellent long-sleeved gown with a plastic apron, double gloves, face shield, and boot cover.

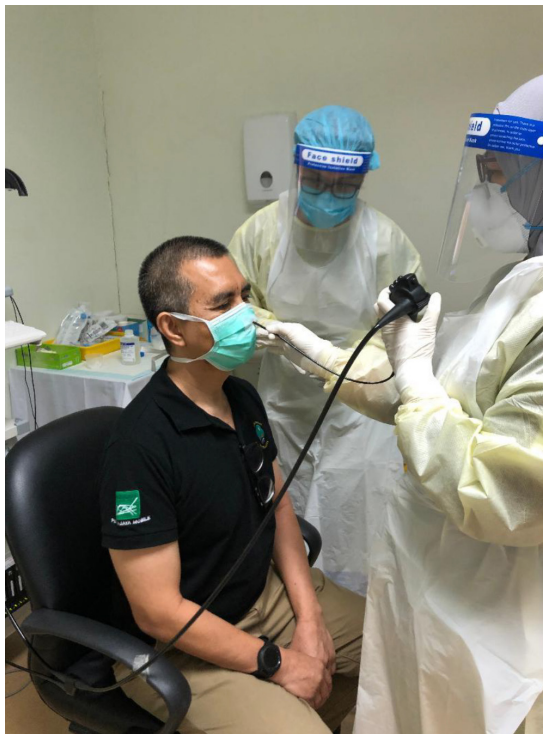At the end of the endoscopy, the patient disclosed that he is a person under investigation (PUI) for COVID-19 as he had direct contact with a patient who was found to be COVID-19 positive while he was in the SARI ward. A repeat chest x-ray showed worsening of ground glass appearance at the lower zone. His second oronasopharyngeal swab was tested positive, and he was then admitted to the COVID-19 ward and started on Hydrochloroquine 200mg B.D., Favipiravir 600mg B.D., and Subcutaneous Interferon 250mcg EOD. His blood parameters were otherwise within normal range except the serum lactate dehydrogenase (LDH) was 544 U/L, and the c-reactive protein (CRP) was 236mg/L, which was slightly raised. Although the arterial blood gases were within a normal range, clinically, the patient was tachypnoeic and required a 3L/min oxygen supplement. Hence, the Covid-19 was staged as category 4a.

A multidisciplinary discussion between head and neck surgeons, intensivists, and infectious disease physicians was then made because of the impending upper airway obstruction with pneumonic changes based on the chest x-ray findings. The decision was to secure the airway with a small endotracheal tube (ETT) followed by tracheostomy in the same setting. The decision was made given the two airway issues (upper and lower airway) and the anticipated difficult airway and inability to insert an appropriate ETT size for efficient ventilation.

A brief simulation was performed before the procedure. Meticulous donning includes powered air-purifying respirator (PAPR) Halo CleanSpace CS3000. A Tyvek suit adhered to all operation theatre personnel consisting of two consultant anaesthetists, a surgeon, an assistant, and a scrub nurse (Figure 2). The patient was transported on a double crank electric hospital bed with a headbox delivering oxygen. A safe distance between the



**Figure 2.** A meticulous donning of enhanced PPE includes PAPR (Halo CleanSpace CS3000) and a Tyvek suit.



**Figure 3.** A patient wears a modified surgical mask as an additional barrier help to contain aerosolization during flexible endoscopy in the clinic.

patient and the medical personnel was ensured during transportation. Since a negative pressure room was unavailable, the patient was operated in a standard operating theatre, but the theatre's laminar flow was turned off. The essential monitors such as the electrocardiogram (ECG), pulse oximeter, intravenous access and closed in-line suction tubing were checked thoroughly to prevent the risk of disconnection and spillage of contaminated blood or other fluids. The patient was intubated uneventfully with ETT size 6.0 mm and it was inserted about 2cm deeper than usual.

After the intubation, the operating team consists of a head and neck surgeon, a senior assistant, and a scrub nurse who wore a sterile gown on top of the enhanced PPE. The patient's neck was extended, and 5.0 ml of Lidocaine 2% was infiltrated as a local anesthetic. A transverse skin incision was made at two finger-breadths above the sternal notch. Upon incising the trachea, the intensivist was reminded to ensure that patient is in total paralysis. The patient was pre-oxygenated with positive end-expiratory pressure (PEEP) before stopping the ventilation, allowing passive expiration, and ETT was clamped. A tracheotomy was carried out by cutting the second and third cartilaginous tracheal rings. There was no diathermy used during the procedure. The ETT was then deflated and pulled proximally until beyond the tracheal window. A 7.5mm double-lumen cuffed non-fenestrated tracheostomy tube was inserted. The ventilation was resumed only when the tracheostomy tube's cuff was inflated, and the circuit was reconnected. The presence of end-tidal volume and chest expansion confirmed the correct placement of the tracheostomy tube. A closed-suction system was incorporated into the catheter mount to allow a closed system suctioning. The entire tracheostomy procedure took less than 10 minutes.

The patient was then transferred to the Intensive Care Unit (ICU) by a different team. Upon completion of the procedure, and when the patient has already been moved out of the operation room, the team doffed the PPE meticulously and then showered using chlorhexidine solution. The ventilator support was weaned down to a tracheostomy mask delivering 2L/min oxygen at third-day post-tracheostomy. Unfortunately, the patient had a cardiac event on day four post-surgery and was reventilated and passed away at day 14. The surgeon and assistant who performed the tracheostomy were well and afebrile (daily temperature measurement) until day 14 after the procedure.



## DISCUSSION

Managing a stridor patient during this COVID-19 pandemic causes a lot of stress and anxiety to the medical team, especially in confirmed cases or a person under investigation (PUI). Performing AGP is inevitable in such cases due to the need to secure the airway by intubation or awake tracheostomy.<sup>5</sup> AGPs involving manipulating mucosa with a high reservoir of the virus will cause suspension of the virus in the air that may remain up to 3 hours.<sup>5</sup> This will put the medical team directly managing the patient at risk of getting the infection. Although there is no emergency in pandemic such cases are time-sensitive that need immediate planning and decision.

Requests to perform tracheostomy is foreseen in prolonged intubated and ventilated COVID-19 cases. It is undoubtedly an AGP representing a significant risk to surgeons, anesthetists, and the operation theatre staff.<sup>8</sup> All aspects of safety and possible transmission of the disease must be considered. It may have potentially unfavorable consequences to the patient and the team. It is essential to revisit the indication, decision and timing for tracheostomy and its prognosis with the intensivists. It should only be considered in patients with stable pulmonary status, not less than 2-3 weeks after intubation<sup>9,10,11</sup> and ideally, with negative COVID-19 status.<sup>5,12,13</sup>

Performing emergency tracheostomy under local anesthesia carries a higher risk of virus transmission because the aerosol production is expected to be more due to involuntary cough reflex during the procedure. In the literature, the first emergency awake tracheostomy was performed in a COVID-19 negative patient.<sup>5</sup> Although the RT-PCR was negative for COVID-19, precautions were made, and the whole team donned enhanced PPE that includes PAPR. Another case of stridor in a PUI was published, but the case was also turned out to be COVID-19 negative.<sup>14</sup> However, management of the case during PUI status was done as it was COVID-19 positive. Flexible endoscopy had to be performed before the RT-PCR test results due to the need to decide on the method of securing the airway. The surgeon donned full PPE with PAPR in a negative pressure room. The patient who was successfully intubated was found to have a tracheal mass. The mass was debulked, and the tracheostomy was deferred as the patient was not keen to have a tracheostomy tube.

The present case is a case of laryngeal carcinoma with impending airway obstruction and concurrent COVID-19 pneumonia. Fortunately, the flexible endoscopy was performed while the surgeon donned full PPE as the hospital guidelines include

an N95 mask. Wearing full PPE during endoscopy in the clinic is recommended considering that some patients are asymptomatic for COVID-19 infections or in the incubation period, and false-negative results were reported in the literature.<sup>3,5,11</sup> Providing an additional barrier by donning a modified surgical mask by a patient may contain the aerosol created during the procedure. [Figure 3](#) depicts a patient who is donning the described modified surgical mask.

The threshold of the decision to secure the airway is low in such a case. Although the patient had a small glottic airway, it was predicted to be intubatable with a small ETT. Therefore, this becomes the primary choice instead of awake tracheostomy. However, the small ETT will not be sufficient for efficient ventilation. Laryngeal edema and stridor are possible in patients with critical illness after extubation.<sup>14</sup> With laryngeal mass and possible laryngeal edema following extubation, the airway obstruction is foreseen to be worse. Therefore, the decision to perform tracheostomy following successful intubation in the same setting for the present case is justified. Specific crucial intraoperative steps need to be adhered to minimize aerosolization during the procedure while performing tracheostomy under general anaesthesia in a COVID-19 positive patient.<sup>15,16</sup> The present case's ORL surgeons and anesthetists went through the guidelines and steps of surgery together and performed the simulation to ensure smooth, quick, and safe surgery. Tracheostomy in COVID-19 positive patients is also recommended to be done in a negative pressure room.<sup>15,16</sup> Due to the unavailability of a negative pressure room in the hospital where the present case is managed, the tracheostomy was performed in a dedicated COVID-19 operation theatre with laminar flow control.

The present case is a suspect case of laryngeal carcinoma with at least T3 clinical tumor staging. To confirm the diagnosis and staging, direct laryngoscopy and C.T. scan are necessary. However, the investigation and procedure were deferred for this patient to minimize exposure and risk of virus transmission to the medical team. Those investigations were planned to be performed once the COVID-19 status becomes negative.

## CONCLUSION

This case highlights the challenge of managing a stridorous patient with laryngeal carcinoma and concurrent COVID-19 positive with pneumonia. The involvement of a multidisciplinary team, adherence to the PPE guidelines, and performing

simulation before the surgery helps determine the methods of securing the airway, protecting the medical team from getting the infection, and providing good patient outcomes. The leading cause of death was not COVID-19 infection but a cardiac event.

## ACKNOWLEDGMENTS

We want to thank the Head of Otorhinolaryngology Department Hospital Kuala Lumpur (Iskandar bin Hailani) and the anesthesiology team (Meor @ Mohd Yusof bin Mohd Mansor, Rohayu binti Othman) in co-managed this patient.

## AUTHOR CONTRIBUTION

All authors have contributed to all process in this research, including research design, data collection and its analysis, writing the manuscript for article publication.

## FUNDING

The authors are responsible for all of the study funding without grants or any external source of funding.

## CONFLICT OF INTEREST

The authors declare no conflict of interest regarding the publication of this article.

## REFERENCES:

1. Coronavirus disease (COVID-19) – World Health Organization [Internet]. Who.int. 2020 [cited 6 November 2020]. Available from: <https://www.who.int/emergencies/diseases/novel-coronavirus-2019>.
2. COVID-19 (Maklumat Terkini) [Internet]. Portal Rasmi Kementerian Kesihatan Malaysia. [cited 2020Nov7]. Available from: <http://www.moh.gov.my/ncov2019>
3. Rameau A, Young V, Amin M, Sulica L. Flexible Laryngoscopy and COVID-19. *Otolaryngology–Head and Neck Surgery*. 2020;162(6):813-815.
4. Mawaddah A, Gendeh H, Lum S, Marina M. Upper respiratory tract sampling in COVID-19. *Malays J Pathol*. 2020;42(1):23-35.
5. Crossley J, Clark C, Brody F, Maxwell J. Surgical Considerations for an Awake Tracheotomy During the COVID-19 Pandemic. *Journal of Laparoendoscopic & Advanced Surgical Techniques*. 2020;30(5):477-480.
6. Wang J, Zhou M, Liu F. Reasons for healthcare workers becoming infected with novel coronavirus disease 2019 (COVID-19) in China. *Journal of Hospital Infection*. 2020;105(1):100-101.
7. Mackintosh T. Coronavirus: First working NHS surgeon dies in U.K. from Covid-19 [Internet]. BBC News. BBC; 2020 [cited 2020Nov7]. Available from: <https://www.bbc.com/news/uk-england-london-52064450>
8. Patel Z, Fernandez-Miranda J, Hwang P, Nayak J, Dodd R, Sajjadi H et al. In Reply: Precautions for Endoscopic Transnasal Skull Base Surgery During the COVID-19 Pandemic. *Neurosurgery*. 2020;87(2):E162-E163.
9. Andriolo N, Andriolo B, Saconato H, Atallah N, Valente O. Early versus late tracheostomy for critically ill patients [Internet]. The Cochrane database of systematic reviews. U.S. National Library of Medicine; [cited 2020Nov7]. Available from: <https://pubmed.ncbi.nlm.nih.gov/25581416/>
10. Curry S, Rowan P. Laryngotracheal Stenosis in Early vs Late Tracheostomy: A Systematic Review. *Otolaryngology–Head and Neck Surgery*. 2019;162(2):160-167.
11. Lavinsky J, Kosugi E, Baptistella E, Roithmann R, Dolci E, Ribeiro T et al. An update on COVID-19 for the otorhinolaryngologist – a Brazilian Association of Otolaryngology and Cervicofacial Surgery (ABORL-CCF) Position Statement. *Brazilian Journal of Otorhinolaryngology*. 2020;86(3):273-280.
12. Clinical management of severe acute respiratory infection when Novel coronavirus (2019-nCoV) infection is suspected: Interim Guidance. [Internet]. [cited 2020Nov7]. Available from: <https://www.who.int/docs/default-source/coronaviruse/clinical-management-of-novel-cov.pdf>.
13. Rassekh C, Jenks C, Ochroch E, Douglas J, O'Malley B, Weinstein G. Management of the difficult airway in the COVID -19 pandemic: Illustrative complex head and neck cancer scenario. *Head & Neck*. 2020;42(6):1273-1277.
14. McGrath B, Wallace S, Goswamy J. Laryngeal oedema associated with COVID -19 complicating airway management. *Anaesthesia*. 2020;75(7):972-972.
15. Tracheostomy guidance during the COVID-19 Pandemic [Internet]. Entuk.org. 2020 [cited 6 November 2020]. Available from: <https://www.entuk.org/tracheostomy-guidance-during-covid-19-pandemic>.
16. Tracheotomy Recommendations During the COVID-19 Pandemic [Internet]. American Academy of Otolaryngology-Head and Neck Surgery. 2020 [cited 6 November 2020]. Available from: <https://www.entnet.org/content/tracheotomy-recommendations-during-covid-19-pandemic>.



This work is licensed under a Creative Commons Attribution